

Novel alternative for submental intubation - A case report -

Inyoung Jung, Byung Hoon Yoo, Ji Youn Ju, Sijin Choi,
Jun Heum Yon, Kye-Min Kim, Yun-Hee Lim, and Woo Yong Lee

Department of Anesthesiology and Pain Medicine, Sanggye Paik Hospital, Inje University College of Medicine, Seoul, Korea

Received July 24, 2019
Revised September 24, 2019
Accepted September 25, 2019

Corresponding author

Byung Hoon Yoo, M.D., Ph.D.
Department of Anesthesiology and
Pain Medicine, Sanggye Paik Hospital,
Inje University College of Medicine,
1342 Dongil-ro, Nowon-gu, Seoul
01757, Korea
Tel: 82-2-950-1170
Fax: 82-2-950-1323
E-mail: twowind@paik.ac.kr

Background: Submental intubation is commonly used during general anesthesia for maxillofacial surgeries as it provides a safe unrestricted surgical access compared to tracheostomy. During submental intubation, soft tissues and blood clots can become lodged in the endotracheal tube. To overcome this problem, we used a laparoscopic trocar.

Case: A 52-year-old male with maxillofacial injury was scheduled to undergo an open reduction and internal fixation. We performed submental intubation using laparoscopic trocar, which created sufficient space for the insertion of the endotracheal tube. Unlike conventional methods, our method did not require any blunt dissection and caused significantly less soft tissue damage and required significantly less time.

Conclusions: Submental intubation with laparoscopic trocar is a one-step method and is quick and easy-to-perform technique with less complications.

Keywords: Airway management; Intubation, intratracheal; Maxillofacial injuries; Trocar.

Submental intubation is commonly performed during general anesthesia for maxillofacial surgeries, especially in cases where nasotracheal intubation can cause potential complications, including epistaxis, accidental cranial or intracranial intubation, and meningitis [1-5]. Furthermore, the presence of comminuted midface or nasoethmoidal complex fractures in maxillofacial injuries may lead to the luminal occlusion of the nasotracheal tube by nasal turbinates, mucous, blood clots. While nasotracheal intubation interferes with the surgical approach during maxillofacial surgeries, submental intubation provides undisturbed and safe surgical access [4,5]. Moreover, it can be reversed after surgery, allowing easy extubation of the patient. In addition, this technique avoids the potentially serious complications of surgical tracheostomy [6-8]. Therefore, submental intubation is widely used in maxillofacial surgeries.

There are several modifications of this technique, including the Seldinger technique and use of percutaneous tracheostomy dilatation kit [6,7]. However, these modifications are associated with potential problems, such as occlusion of endotracheal tube by soft tissues and blood clots. Therefore, we attempted to identify a more effective way of submental intubation. A laparoscopic trocar consists of trocar sleeve and trocar needle. After creation of a passage with trocar in the desired position, the trocar needle is removed and the instrument is inserted subsequently through the trocar sleeve.

We performed submental intubation by using a laparoscopic trocar in making a submental passage. The trocar was then used as a passage for inserting the endotracheal tube. The use of a laparoscopic trocar reduced trauma and intubation time.

CASE REPORT

Informed consent was obtained from the patient for the publication of this report.

A 52-year-old male with fractures of the zygomaticomaxillary, zygomatic arch, and right inferior orbital floor (Lefort II fracture) was scheduled to undergo open reduction and internal fixation. For this patient, instead of conventional nasotracheal intubation, we planned a submental intubation because nasotracheal intubation in patients with Lefort II or III fracture can lead to potential complications, such as intracranial intubation, meningitis, and the luminal occlusion of endotracheal tube by nasal turbinates, mucous, and blood clots. However, even submental intubation has several complications associated with its use. To overcome these problems, we used a 12-mm laparoscopic trocar (Laport, Korea) for pulling out the endotracheal tube from the oral cavity to the submental area during submental intubation. Before the procedure, we confirmed that the armored endotracheal tube (internal diameter, 7.5 mm) could pass through the trocar. After removal of the connector of the armored tube, the endotracheal tube was passed through the trocar's 12-mm diameter internal lumen (Fig. 1).

After standard orotracheal intubation, the tongue was retracted to expose the floor of the mouth. After making a 1.5-cm incision, the 12-mm laparoscopic trocar was passed in the skin-to-oral direction. After ventilating the patient with 100% oxygen for several minutes, the tracheal tube was briefly disconnected from the breathing circuit. The connector of the armored tube was removed and the proximal part of the tube was pulled through the passage in the lumen of the trocar. Thereafter, the trocar was removed. The connector was reattached and the tube was reconnect-

ed to the breathing circuit (Fig. 2). The position of the tracheal tube was checked using capnography and chest auscultation, and the distance marking on the endotracheal tube at the exit site on the skin was carefully noted. The tube was then secured to the skin of the submental region with a heavy (20) black silk suture. The surgery was successful and without any adverse effects. After completion of the surgery, the abovementioned procedures were reversed. The skin sutures were cut, and the tracheal tube was briefly disconnected from the breathing circuit. Thereafter, the connector was removed and the tube was pulled back through the passage in the floor of the mouth. The connection was then reestablished and the tube was secured. The submental incision was closed using three monofilament skin sutures, which were removed 5–7 days postoperatively. No attempt was made to close the oral defect.

The use of a laparoscopic trocar for submental intubation significantly reduced the inflow of soft tissues and blood into the endotracheal tube. This method was much easier than the passing the tube from the oral cavity to the submental incision site.

DISCUSSION

Submental intubation is an effective alternative for airway management in select patients undergoing surgery for maxillofacial injuries. It avoids complications associated with tracheostomy, such as hemorrhage, emphysema, tube blockage, tracheal stenosis, and scarring [6,8,9]. In addition, it provides unrestricted access to the surgical site. Generally, submental intubation is performed after standard orotracheal intubation. After submental incision and dissection towards the mouth floor, the proximal part of

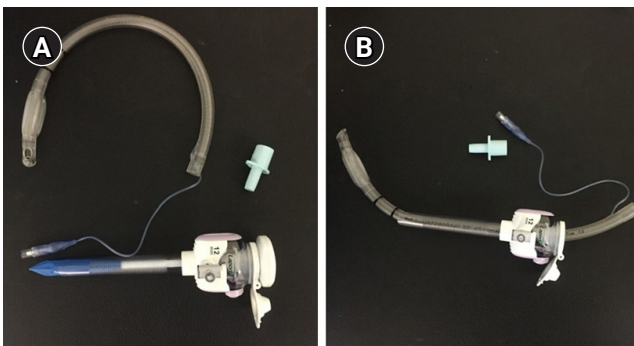


Fig. 1. (A) Removal of the armored tube connector. (B) The armored endotracheal tube (internal diameter, 7.5 mm) passes through the 12-mm diameter lumen of the laparoscopic trocar.

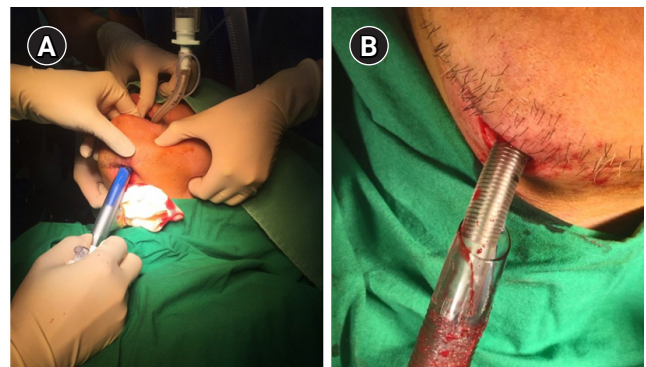


Fig. 2. (A) The 12-mm laparoscopic trocar is inserted in the skin-to-oral direction. (B) The tube is pulled through the passage of the trocar's lumen.

the endotracheal tube is pulled out through the submental incision. However, this process is difficult because soft tissues and blood clots can cause luminal occlusion of the endotracheal tube. The outer diameter of the armored endotracheal tube used in our case was 10.3 mm. However, because of the connection between the E-tube and the pilot line, a trocar with an inner diameter slightly larger than 10.3 mm was required. Before using the trocar, we verified that the 7.5-mm inner diameter E-tube could pass through the 12-mm laparoscopic trocar. In our experience, it is advisable to use a trocar with an inner diameter of approximately 1–2 mm larger than the outer diameter of the endotracheal tube. In our case, a laparoscopic trocar offered sufficient space for the passage of the endotracheal tube. Injury to Wharton's duct, sublingual salivary gland, and other vital structures, such as the lingual nerve in the floor of mouth, are potential complications that can arise during submental intubation due to misplacement of the trocar. In our case, the direction was set by inserting the trocar into the initial incision at the passage similar to that applied during conventional blunt dissection. Therefore, the degree of damage with submental intubation is considered to be similar with that occurring during the conventional method [10]. Moreover, we did not perform blunt dissection, and thus, caused minimal soft tissue damage. Previously, it took 15–20 min to perform the Kelly's blunt dissection, mostly because of the prolonged time needed to create sufficient space for the passage of the endotracheal tube through the submental area; however, the percutaneous tracheostomy dilatation kit took less than 10 min [11,12]. However, our technique required significantly less time (< 5 min). Additionally, the endotracheal tube did not occlude because of reduced soft tissue damage and minimal hemorrhage. Moreover, the laparoscopic trocar is a device which is easily accessible in the operating room. Thus, the use of a laparoscopic trocar for submental intubation is a rapid one-step method, which is easy and quick to perform with minimal complications.

We therefore recommend performing the submental intubation technique using a laparoscopic trocar.

CONFLICTS OF INTEREST

No potential conflict of interest relevant to this article was reported.

AUTHOR CONTRIBUTIONS

Conceptualization: Byung Hoon Yoo, Inyoung Jung. Data acquisition: Ji Young Ju, Sijin Choi. Writing—original draft: Inyoung Jung. Writing—review & editing: Byung Hoon Yoo, Jun Heum Yon, Kye-Min Kim, Yun-Hee Lim, Woo Yong Lee.

ORCID

Inyoung Jung, <https://orcid.org/0000-0002-6221-9177>
 Byung Hoon Yoo, <https://orcid.org/0000-0002-1958-8380>
 Ji Youn Ju, <https://orcid.org/0000-0001-9069-4189>
 Sijin Choi, <https://orcid.org/0000-0003-1860-3320>
 Jun Heum Yon, <https://orcid.org/0000-0002-2997-2191>
 Kye-Min Kim, <https://orcid.org/0000-0003-1298-7642>
 Yun-Hee Lim, <https://orcid.org/0000-0003-2399-4768>
 Woo Yong Lee, <https://orcid.org/0000-0002-1632-1314>

REFERENCES

1. Bähr W, Stoll P, Schilli W, Scheramet R. [Nasal intubation for frontobasal fractures?]. *Dtsch Zahnarzt Z* 1992 47: 43-5. German.
2. Junsanto T, Chira T. Perimortem intracranial orogastric tube insertion in a pediatric trauma patient with a basilar skull fracture. *J Trauma* 1997; 42: 746-7.
3. Schade K, Borzotta A, Michaels A. Intracranial malposition of nasopharyngeal airway. *J Trauma* 2000; 49: 967-8.
4. Joo DT, Orser BA. External compression of a nasotracheal tube due to the displaced bony fragments of multiple LeFort fractures. *Anesthesiology* 2000; 92: 1830-2.
5. Sprung J, Bourke DL, Harrison C, Barnas GM. Endotracheal tube and tracheobronchial obstruction as causes of hypoventilation with high inspiratory pressures. *Chest* 1994; 105: 550-2.
6. Ujam A, Perry M. Minimally traumatic submental intubation: a novel dilational technique. *Eur J Trauma Emerg Surg* 2017; 43: 359-62.
7. Walker DG. Complications of tracheostomy: their prevention and treatment. *J Oral Surg* 1973; 31: 480-2.
8. Kita R, Kikuta T, Takahashi M, Ootani T, Takaoka M, Matsuda M, et al. Efficacy and complications of submental tracheal intubation compared with tracheostomy in maxillofacial trauma patients. *J Oral Sci* 2016; 58: 23-8.
9. de Toledo GL, Bueno SC, Mesquita RA, Amaral MB. Complications from submental endotracheal intubation: a prospective study and literature review. *Dent Traumatol* 2013; 29: 197-202.
10. Tidke AS, Borle RM, Madan RS, Bhole ND, Jadhav AA, Bhoyar AG. Transmyloheid/submental endotracheal intubation in pan-facial trauma: a paradigm shift in airway management

- with prospective study of 35 cases. *Indian J Otolaryngol Head Neck Surg* 2013; 65: 255-9.
11. Saheb SM, Nath VN, Kumar KP, Padmaja PP. A novel method using Seldinger's technique for submental intubation in major craniomaxillofacial fractures: a case series. *Indian J Anaesth* 2014; 58: 48-50.
12. Biswas BK, Joshi S, Bhattacharyya P, Gupta PK, Baniwal S. Percutaneous dilational tracheostomy kit: an aid to submental intubation. *Anesth Analg* 2006; 103: 1055.