

New Device For Submental Endotracheal Intubation

Roger Lanes Silveira, PhD,^{*†‡} Samuel Macedo Costa, DDS,^{*}
and Marcio Bruno Figueiredo Amaral, PhD^{*}

Abstract: The submental intubation is a well-described technique as an alternative for the tracheostomy in the airway management in patients with contraindications for the nasotracheal and cannot remain in the orotracheal position due to the need to maintain the intermaxillary fixation. Residents and young oral and maxillofacial surgeons could have experienced some difficulty performing the technique first described by Altemir (1986). This report aims to describe a new device designed to facilitate and simplify the technique helping surgeons on the submental endotracheal intubation.

Key Words: Airway management, craniomaxillofacial trauma, submental intubation

(*J Craniofac Surg* 2020;00: 00–00)

Submental endotracheal intubation was 1st described by Altemir in 1986. This well-described technique is an alternative for the tracheostomy in the airway management in patients with contraindications for the nasotracheal or orotracheal intubation. The procedure originally described an initial oral intubation with a reinforced endotracheal tube, followed by exteriorization of the endotracheal tube through a soft-tissue tunnel created via a subperiosteal dissection through a 20-mm paramedian incision made on the skin in the submental region and mucosa on the lingual aspect of the mandible.^{1,2}

The authors designed a device to accelerate the traditional technique, eliminating risks inherent to the transposition of the tube. This study aims to describe a new device designed to accelerate the technique helping surgeons on the submental endotracheal intubation.

TECHNICAL NOTE

This present device was registered and protected under the patent BR 1020180757911 and the present study was approved by the

From the ^{*}Oral and Maxillofacial Surgery Residency Program, Hospital João XXIII/FHEMIG; [†]Otorhinolaryngology and Head and Neck Surgery Service, Santa Casa; and [‡]Otorhinolaryngology and Head and Neck Surgery Service/Craniomaxillofacial Surgery Team, Hospital Mater Dei, Betim/Contagem, Brazil.

Received July 7, 2019.

Accepted for publication September 30, 2019.

Address correspondence and reprint requests to Roger Lanes Silveira, PhD, Samuel Macedo Costa, DDS, Oral and Maxillofacial Surgery Residency Program, Hospital João XXIII/FHEMIG, Av. Alfredo Balena, 400, Santa Efigênia, Belo Horizonte-MG, CEP 30130-100, Brazil;

E-mails: rogerlanes@yahoo.com.br, samuel.macedo.costa@gmail.com

The authors report no conflicts of interest.

Copyright © 2020 by Mutaz B. Habal, MD

ISSN: 1049-2275

DOI: 10.1097/SCS.00000000000006129

ethics committee under the number 92372518.2.0000.5119. The present device is composed of 3 parts: conical punch device, coupled cylinder pliers, and tongue retractor and drilling guide (Fig. 1A-C).

The preparation of the reinforced tube is carried out in a standard fashion as described by Altemir.¹ However, only a 10-mm width incision is performed in the submental midline. The submental device is introduced with the tip of the blunt object piercing the tissues without causing cuts, avoiding tissue damages, such as those that may occur in the usual dissection. The course of the device through the tissue layers is performed without major difficulties. The tip of the device emerges in the mouth in the tongue retractor, which has a guiding function to the device.

The cylinder is then removed and the pliers will allow passage of the cuff initially and then the tube itself into the outer region of the submental skin. Then, the plastic connection is reinserted and connected to the mechanical ventilation equipment (Fig. 2). External fixation of the tube in the submental skin as well as conventional technique is indicated. After the end of the surgical procedure, the tube should be returned in the same manner as described in the literature.

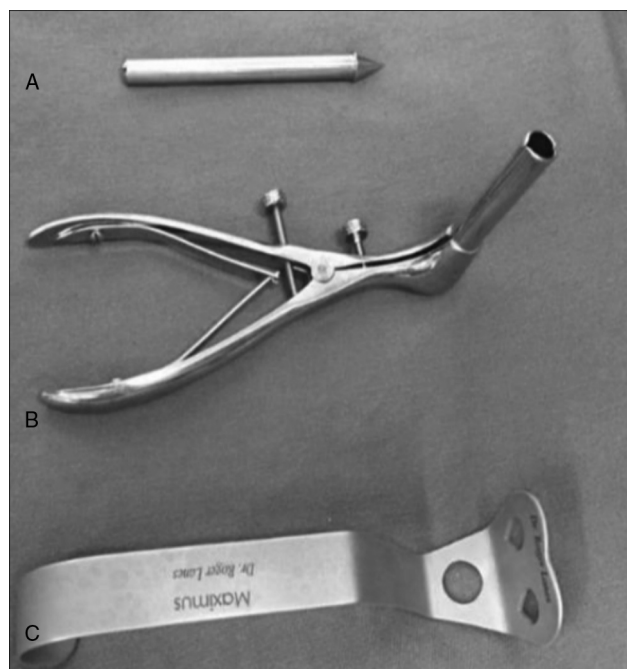


FIGURE 1. Photograph showing the submental device kit for transposition of the orotracheal tube. (A) Conical punch device. (B) Coupled cylinder pliers. (C) Tongue retractor and drilling guide.

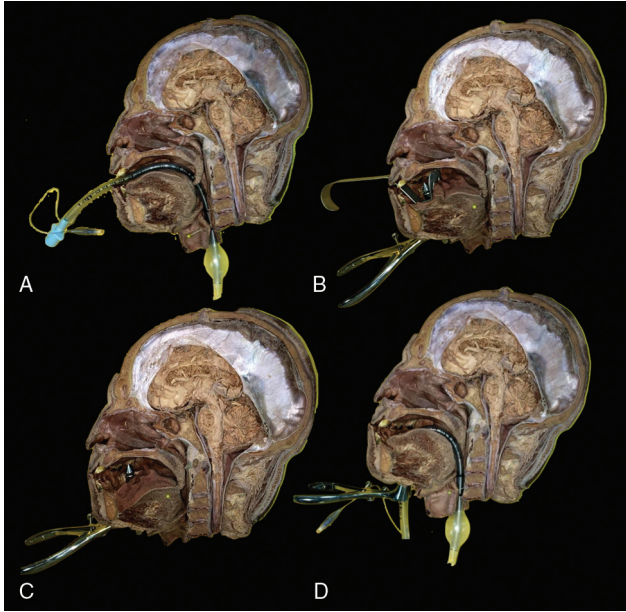


FIGURE 2. Cadaver photograph demonstrating the process of submental intubation by the technique proposed in this paper. (A) Normal orotracheal intubation process. (B) Insertion of the device on the submental position. (C) Image demonstrating patency of the device on the mouth floor. (D) Photograph demonstrating the transposition of the tube for the submental position.

DISCUSSION

The submental endotracheal intubation is a reliable alternative for the tracheostomy on the airway management mainly in trauma patients diagnosed with skull base fracture that needs surgical procedures for the correction of facial fractures.^{2,3}

Although common and safe, the classic technique presents complications already described in the literature as skin infection, salivary fistula, accidents related to the tube, unaesthetic scar, bleeding, and abscess in the floor of the mouth.⁴

This new device proposed in this present study did not alter the most common complications. However, it reduces the chance of accidents related to the tube and decreases the impact of the scar. Finally, this device should be able to help the surgeons to perform submental endotracheal intubation without major difficulties, accelerating the technique and increasing its use to the detriment of poorly indicated tracheostomies.

REFERENCES

1. Altemir FH. The submental route for endotracheal intubation. *J Maxillofac Surg* 1986;14:64–65
2. Lim D. Submental intubation - practical alternative airway in maxillofacial surgeries. *J Clin Anesth* 2017;41:97–98
3. Kaiser A, Semanoff A, Christensen L, et al. Submental intubation: an underutilized technique for airway management in patients with panfacial trauma. *J Craniofac Surg* 2018;29:1349–1351
4. De Toledo GL, Bueno SC, Mesquita RA, et al. Complications from submental endotracheal intubation: a prospective study and literature review. *Dent Traumatol* 2013;29:197–202