J Oral Maxillofac Surg
56:302-306, 1998

Retromolar Intubation

J.L. Martinez-Lage, MD, DMD, J.M. Eslava, MD,† A.I. Cebrecos, MD,‡ and O. Marcos, MD§*

Purpose: A simple technique of retromolar intubation does not interfere with dental occlusion and offers clear advantages in craniofacial, orthognathic, oncologic, and trauma surgery procedures.

Patients and Methods: Thirty-nine subjects underwent different surgical procedures using this intubation technique. The possible surgical and anesthetic complications were analyzed.

Results: After the analysis of the studied variables and modes, we noticed that there was not a significant increase in complications or surgical time compared with other classic intubation methods. A retromolar bone graft could be obtained if necessary.

Conclusion: This technique does not impede operating on the nasal pyramid and allows intraoperative assessment of the new surgical profile, while permitting establishment of normal occlusion.

Interdental occlusion necessary for craniofacial and orthognathic surgery is not possible with conventional oral intubation; therefore, nasotracheal intubation is the option of choice.[1-6] However, distortion generated by the nasotracheal tube impedes a correct assessment of the patient's profile and causes nasal surgery to be done as a secondary procedure. Classic oral and nasotracheal intubation modes are unsatisfactory in certain situations such as simultaneous orthognathic and rhinoplasty surgery and orthognathic surgery in cleft patients because a perfect nasal floor reconstruction is necessary[7]; pancraniomaxillofacial fractures, which require simultaneous treatment of all the fragments[8]; and in oncologic cranial base surgery.

Different solutions can be used for this problem, one of the most accepted being to perform a temporary tracheostomy. Other techniques such as placing the tube through an edentulus area if teeth are missing,[7] through the space between the maxillary tuberosity and the mandibular ramus (retrotuberosity intubation),[7] submental intubation,[9] an indexed splint used to allow for maxillomandibular fixation (MMF) around an orotracheal tube,[10] and converting from nasal to an oral endotracheal tube with or without extubation[11-13] have been described.

We describe a method involving placement of a flexible armored tube in the retromolar area. We have been using this method since February 1992, when it first enabled us to proceed with Le Fort III plus Le Fort I osteotomies with MMF and simultaneous rhinoplasty in a patient with Apert's syndrome.

Patients and Methods

Thirty-nine consecutive patients undergoing retromolar intubation were studied. Distribution of procedures was: 22 orthognathic surgery cases, 14 craniofacial procedures, two pancraniomaxillofacial cases, and one cranial base approach in an oncologic procedure.

To evaluate the results of the surgical technique, the following parameters were assessed: time of surgery, need for third molar extraction, possibility of obtaining bone grafts, complications, interference with arch bars, mandibular fracture while performing osteotomies, accidental extubation, and intraoperative tube injuries. The time required for fixation of the tube was calculated, starting from when the anesthesiologist completed the orotracheal intubation.

SURGICAL TECHNIQUE

Once orotracheal intubation with a wire-reinforced tube had been completed, an angled retromolar incision was made in the mandibular trigonregion. Using the side opposite to the surgeon is more convenient and provides for an easier profile assessment. If a third molar was found, whether erupted or unerupted, it is extracted before performing a semilunar (180°) osteotomy large enough for the tube to lie below the occlusal plane (Fig 1A). The osteotomy was slightly angled (from ventral to dorsal and from lateral to

Received from the Department of Craniomaxillofacial Surgery, Ramón y Cajal University Hospital, Madrid, Spain.

*Head.

†Staff Member.

‡Senior Resident.

§Senior Resident.

Address correspondence and reprint requests to Dr Martinez-Lage: Departamento de Cirugía Craneomaxilofacial, Hospital Ramón y Cajal, Ctra Colmenar Viejo, km 9'100, 28034 Madrid (Spain).

0278-2391/98/5603-0005$3.00/0

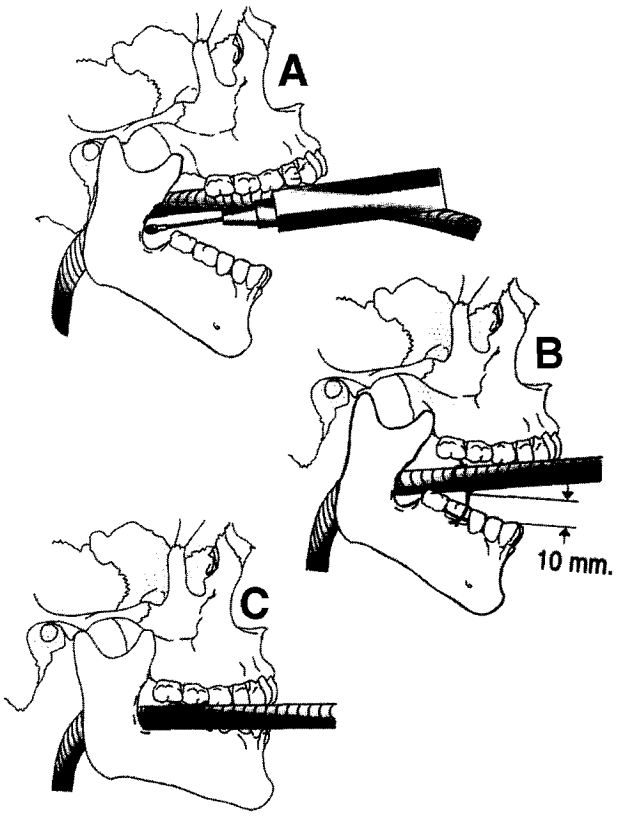

FIGURE 1. *A,* Semilunar osteotomy according to the diameter of the tube is performed in the mandibular trigonum. *B,* The tube is stabilized by wire ligatures to the first molar, leaving an 8- to 10-mm gap between molar and tube. *C,* The tube is left undisturbed in this position and does not interfere with dental occlusion.

medial) to avoid bending of the tube. During the osteotomy, the internal mucoperiostal plane was protected to prevent injuries to the lingual nerve. If bone grafts were needed, the osteotomy was designed to obtain a segment of retromolar bone simultaneously. The mucoperiostal flap was replaced after checking that the tube did not impede the occlusion. The flap was sutured, or simply left in place if the ipsilateral ramus of the mandible is to be operated on. The tube was stabilized to the first or second molars by wire ligatures, leaving an 8- to 10-mm space between the teeth and tube (Fig 1B). The tube was left in this position throughout the procedure (Fig 1C). However, if the ipsilateral mandibular ramus or body region was operated on, it was temporarily displaced medially (Fig 2). If mandibular retropositioning through sagittal ramus osteotomies was done, a small notch was needed in the proximal fragment to avoid interference with the tube.

Retromolar intubation can be performed without osteotomy in a few patients.[14] This anatomic possibility can be determined by introducing the index finger in the patient's mouth and asking him or her to close their mouth slowly. However, occlusal changes derived from the osteotomy must be considered in this appraisal.

The mean intubation time in the intensive care unit for patients with MMF ranged from 8 to 20 hours. It is well known that oral intubation is poorly tolerated when the mouth remains open. However, after MMF, oral tubes are much better tolerated than nasal tubes.

Results

No complications involving the surgical technique occurred. In three patients, the position of the tube hindered the positioning of dental fixation appliances. There were no tube injuries, accidental extubations, or postoperative complications.

Mean time for tube placement was 25 minutes. Eight patients required extraction of the third molar, which prolonged the mean time to 33 minutes. Bone fragments obtained from the procedure were used as bone grafts, especially for the nasal dorsum, in five patients (Fig 3).

It was not possible to compare tolerance of the nasotracheal and orotracheal tube because it is a subjective variable, and the same patient should experience both types to obtain significative data. However, we noticed fewer complaints from patients with retromolar fixed tubes when MMF was used due to the tube being totally immobilizated.

Discussion

Several alternatives to nasal intubation have been proposed, but none are without complications. The inconveniences observed with our technique are the increased operating time, although we believe this is

FIGURE 2. The tube is medially displaced if the ipsilateral mandibular side is to be operated on.

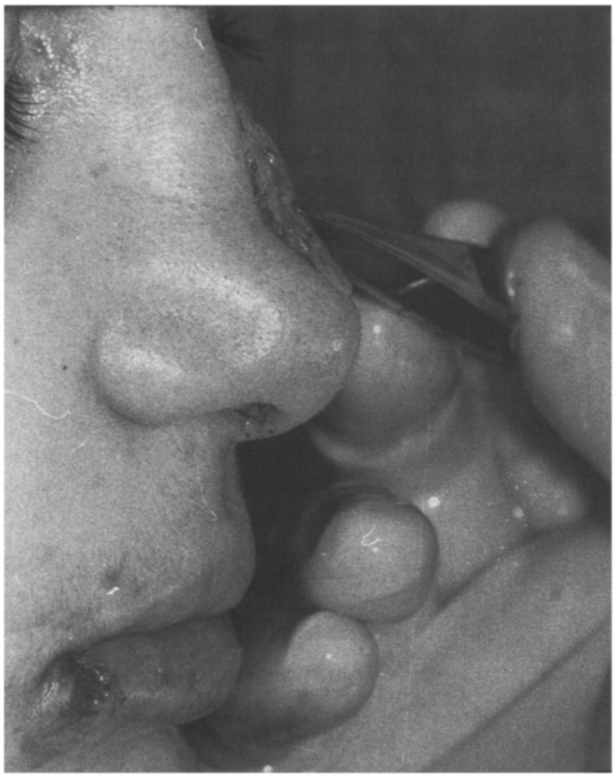

FIGURE 3. Immediately after two-jaw osteotomies, a rhinoplasty is performed, using a trigonum bone graft for nasal dorsum.

not significant when considering the total time of the procedure, and the possible interference when placing dental fixation appliances. However, nowadays these appliances are placed preoperatively in most of the patients who undergo these surgical procedures.

Conversely, this technique avoids damage to the tube during the osteotomies because of the visualization of the tube,[15-18] morbidity associated with tracheostomy, and secondary surgical procedures to complete the treatment. Furthermore, bone graft can be obtained for several areas when necessary.

Among the other advantages and applications we have found are:

1. In orthognathic surgery of the maxilla, the nasolabial angle, dental exposure, and widening of the alar base can be assessed more accurately.
2. Nasal reconstruction can be done during orthognathic procedures in cleft patients.[7]
3. In two-jaw osteotomies (Fig 4), the new surgical profile and quantitative results of genioplasties can be much better assessed.
4. It allows simultaneous maxillomandibular and nasal surgery.[13,19,20]
5. In craniofacial osteotomies of the middle facial third, better mobilization with Rowe's forceps can be obtained without transmitting pressure to the nasoendotracheal tube (Fig 5); bony advancement and dental occlusion are under better control, and nasal surgery that is necessary in most patients is not impeded.
6. In trauma surgery involving the middle third of the face, maxillary and nasal fractures can be treated simultaneously. Furthermore, the technique avoids complications due to nasal intubation in craniofacial trauma, such as meningitis, or intracranial placement of the nasal tube in patients with frontobasilar fractures.[8,21,22]
7. In oncologic procedures of the cranial base, transfacial approaches are made easier by retromolar intubation, because it allows a greater descent of the maxilla after a Le Fort 1 osteotomy, exposing the whole cranial base. If splitting of the maxilla is necessary, both fragments can be correctly replaced with rigid fixation without altering the occlusion.

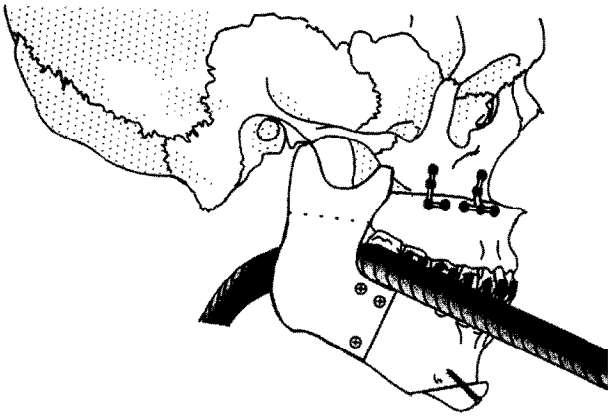

FIGURE 4. In two-jaw osteotomies, the new surgical profile can be much better assessed, and the nose can be operated on.

We believe that in certain situations this simple intubation technique is the procedure of choice when

FIGURE 5. In craniofacial osteotomies of the middle third, a better mobilization with Rowe's forceps can be obtained; bony advancement and dental occlusion are under control, and nasal surgery is not impeded.

the conventional intubation methods do not offer a satisfactory solution.

References

1. Crysdale WS: Airway management in craniofacial surgery. J Otolaryngol 16:207, 1987
2. Munro IR: Craniofacial surgery: Airway problems and management. Int Anaesthesiol Clin 26:72, 1988
3. Handler SA: Craniofacial surgery: Otolaryngology concerns. Int Anaesthesiol Clin 26:61, 1988
4. Hilley HD, Ghali GE, Giesecke AH: Anesthesia for orthognathic and craniofacial surgery, *in* Bell HW: Modern Practice in Orthognathic and Reconstructive Surgery, vol 1. Philadelphia, PA, Saunders, 1992
5. Murphy A: Anesthesia for orthognathic surgery. Int Anesthesiol Clin 27:98, 1989
6. Weaver JH: Contemporary anesthetic techniques for orthognathic surgery. Anesth Prog 39:146, 1992
7. Schendel SA, Delaire J: Functional musculo-skeletal correction of secondary unilateral cleft lip deformities: Combined lip-nose correction and Le Fort 1 osteotomy. J Maxillofac Surg 9:108, 1981
8. Schultz RC: Nasotracheal intubation in the presence of severe facial fractures. Plast Reconstr Surg 86:1046, 1990 (letter)
9. Hernadez AF: The submental route for endotracheal intubation. J Maxillofac Surg 14:64, 1986
10. Farole A, Protrowski JC: A unique indexing splint for use in combined Le Fort and nasal injuries to avoid tracheostomy. Oral Surg Oral Med Oral Pathol 70:399, 1990
11. Werther JR, Richardson G, McIlwain MR: Nasal tube switch: Converting from a nasal to an oral endotracheal tube without extubation. J Oral Maxillofac Surg 51:168, 1993 (suppl 3)
12. Werther JR, Richardson G, McIlwain MR: Nasal tube switch: Converting from a nasal to an oral endotracheal tube without extubation. J Oral Maxillofac Surg 52:994, 1994
13. Kinnebrew MC, Emison JW: Simultaneous maxillary and nasal reconstruction. J Craniomaxillofac Surg 15:312, 1987
14. McCarthy JG: Converse, *in* Cirugía Plastica: La Cara. Panamericana, 1992, p 35
15. Fagraeus L, Angelillo JC, Dolan EA: A serious anesthesia hazard during orthognatrhic surgery. Anesth Analg (Cleve) 59:150, 1980
16. Pagar DH: Cutting of nasoendotracheal tube: An unusual complication of maxillary osteotomies. J Oral Surg 36:314, 1978
17. Mosby EL: Intraoperative damage to nasotracheal tube during maxillary surgery: Report of cases. J Oral Surg 36:963, 1978
18. Schwartz LB, Sordill WC, Liebers RM, et al: Difficulty in removal of accidentally cut endotracheal tube. J Oral Maxillofac Surg 40:518, 1982
19. Waite PD, Matukas VJ: Simultaneous rhinoplasty procedures in orthognathic surgery. Int J Oral Maxillofac Surg 17:298, 1988
20. Waite PD, Matukas VJ: Indications for simultaneous orthognathic and septorhinoplastic surgery. J Oral Maxillofac Surg 49:133, 1991
21. Bahr W, Stoll P: Nasal intubation in the presence of frontobasal fractures. J Oral Maxillofac Surg 50:445, 1992
22. Muzzi DM, Losasso TJ, Cucchiara RF: Complication from a nasopharyngeal airway in a patient with a basilar skull fracture. Anesthesiology 74:366, 1991

J Oral Maxillofac Surg
56:305-306, 1998

Discussion

Retromolar Intubation

John R. Werther, DMD, MD
Assistant Professor, Vanderbilt University School of Medicine, Nashville VA Medical Center, Nashville, Tennessee

Nasal intubation is the technique of choice for airway management in most traumatic and reconstructive maxillofacial surgery procedures. It is a safe, reliable, time-tested technique that provides unimpeded access to the oral cavity. The primary reason not to use nasal intubation in maxillofacial surgery, particularly in the trauma setting, is a priori need for tracheostomy. A variety of solutions to the problem of performing concurrent nasal surgery with a nasotracheal tube (NTT) have been offered. Martinez-Lage et al[1] present a technique of transoral retromolar intubation, ostensibly to allow for improved assessment of profile changes during orthognathic and craniofacial surgery and to permit simultaneous surgery of the nasal pyramid. There are a number of theoretical and practical objections to this method.

First of all, destruction of bony anatomy for the sole purpose of making space for an oral endotracheal tube (ETT) does not make sense, especially when that bone may be useful for fracture or osteotomy segment fixation devices. Second, the determination of skeletal movement and the anticipated soft tissue response is planned before orthognathic surgery and is based on examination of the patient, radiographic analyses, model surgery, and the surgeon's clinical judgment. Tissue swelling, patient position, a partially draped surgical field, and the imponderables of the healing process make it impractical, if not impossible, to predict accurately the long-term soft tissue response to bony changes that are made in the operating room. Third, it is illogical to obstruct the main operative field with an ETT to facilitate access for a lesser, secondary procedure when satisfactory alternatives exist.

Orthognathic surgery patients constituted more than half the study population in this study. It would have been helpful to know what types of osteotomy were performed, the duration of the procedures, and what impediments, if any, were encountered with the execution and fixation of the osteotomies, particularly the sagittal split ramus osteotomy (SSRO). The tube interfered with dental fixation in 8% of cases, but no specifics are mentioned. Performing SSRO can be frustrating even when the patient is intubated nasally. Thus, from a practical standpoint, it is hard to imagine why one would choose to obstruct the operative field with an ETT. The authors use a line drawing (Fig 4) to illustrate three-screw rigid fixation of the SSRO segments,