

LETTER TO THE EDITOR

Airway management by transmylohyoid endotracheal intubation in two cats with mandibular trauma

Airway management can be challenging in animals with maxillofacial trauma. Conventional orotracheal intubation obstructs the assessment of occlusion during surgical repair. Therefore, an alternative technique is indicated to secure the airway while optimizing surgical access. Tracheal intubation through a pharyngotomy is described in textbooks, but scientific reports in cats are scarce (Hartsfield et al. 1977). Transmylohyoid endotracheal intubation has been reported as an alternative in humans and dogs (Gadre & Kushte 1992; Soukup & Snyder 2015). This is a report describing transmylohyoid endotracheal intubation in two cats.

At our hospital, two cats were presented for polytrauma and treated for cardiovascular shock. The 5 month old, female British Shorthair cat weighing 2.4 kg suffered bilateral mandibular fractures with ventral displacement as seen on

computed tomography. The second was a 1.5 year old, female Bengal cat weighing 2.8 kg with a left mandibular fracture. Anaesthesia for mandibular fixation was scheduled after signs of head or thoracic trauma had resolved by 5 and 7 days, respectively. Transmylohyoid endotracheal intubation was planned to facilitate surgery. The cats were premedicated with intravenous (IV) methadone (0.3 and 0.2 mg kg⁻¹, respectively; Methadon; Streuli Pharma AG, Switzerland) and pre-oxygenated by mask. Anaesthesia was induced by administration of midazolam (0.2 and 0.3 mg kg⁻¹, respectively; Dormicum; Roche, Switzerland) IV and propofol titrated to effect (Propofol 1%; Fresenius Kabi, Switzerland). Orotracheal intubation was performed with 3.0 and 3.5 mm internal diameter (ID) cuffed endotracheal tubes, respectively. Anaesthesia was maintained in the first cat with isoflurane in an oxygen and air mixture (inspired oxygen 50%), and in the second cat with sevoflurane in oxygen delivered through rebreathing systems. When cardiopulmonary monitoring was attached, both cats were positioned in dorsal recumbency.

The submandibular region was clipped and aseptically scrubbed for surgery. A curved Halsted mosquito forceps was advanced through the oral cavity to the lingual surface of the carnassial tooth and the curved tip pushed ventrally to be located by palpation of the skin on the ventral aspect of the chin. A skin incision was made with a number 10 scalpel blade on the immediate medial aspect of the ventral body of the mandible at the level of the first molar tooth. Subcutaneous

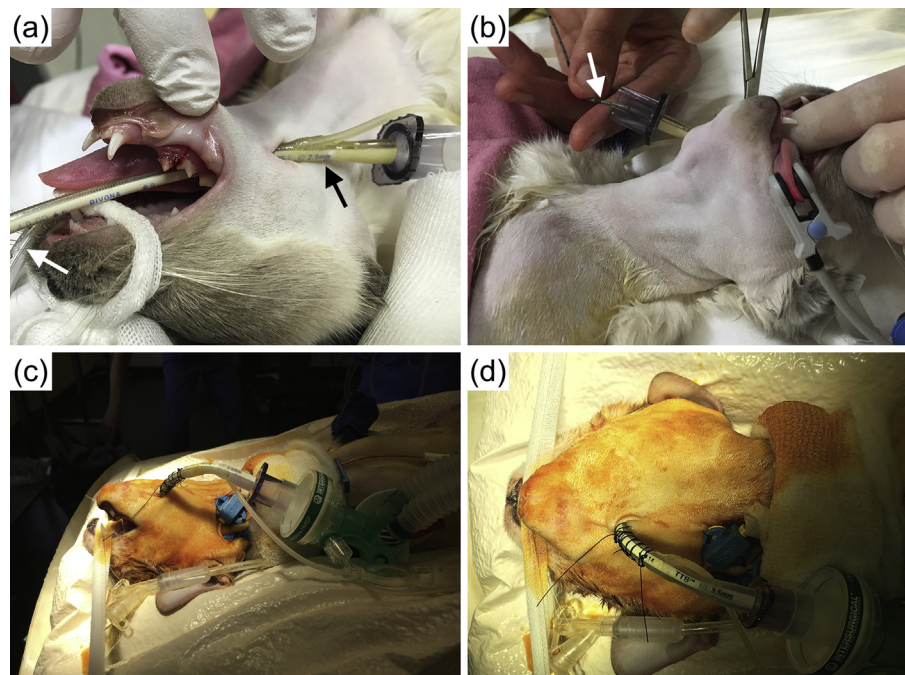


Figure 1 Transmylohyoid endotracheal intubation in two cats. In cat 1 (a) the guarded endotracheal tube (black arrow) was pulled into the oral cavity through the transmylohyoid approach while the conventional orotracheal tube (white arrow) was in place; and (b) a 70 cm urinary catheter (white arrow) was inserted through the conventional orotracheal tube before the orotracheal tube was withdrawn, to be used as a guide for introduction of the guarded endotracheal tube from the transmylohyoid approach into the trachea. In cat 2, (c) depicts a lateral view of the endotracheal tube inserted through the transmylohyoid approach; and (d) view of the transmylohyoid endotracheal tube secured using a Chinese finger-trap friction suture.

tissues and mylohyoid muscles were bluntly dissected. Once the curved forceps was seen through the oral mucosa, an incision exposed the tips of the curved forceps, which were then exteriorized. The forceps were manipulated to clasp the distal end of a guarded 2.5 or 3.5 mm ID cuffed endotracheal tube, and to pull the tube from the oral cavity cranial to the base of the tongue (Fig. 1). At this point, the orotracheal tube was disconnected from the breathing system and a urinary catheter (1.3 mm outside diameter, length 70 cm; Teleflex Medical, Ireland), premeasured from the orotracheal tube connector to the thoracic inlet, was introduced in the lumen as an airway exchange catheter. The orotracheal tube was removed and the guarded endotracheal tube was inserted into the trachea over the airway catheter with help of curved forceps. Once in place, the urinary catheter was removed and the guarded tube was connected to the breathing system. The endotracheal tube was secured in place using a butterfly tape sutured to the skin and a Chinese finger-trap friction suture, respectively (Fig. 1).

Respective external skeletal fixators were placed while assessing correct occlusion without complications. No complications occurred during anaesthesia and after completion of surgery the cat was allowed to recover. Once a swallowing reflex was present, the cat was carefully extubated through the transmylohyoid incision without incident. The incision was left to heal by secondary intention. In both cats, no adverse events associated with the transmylohyoid intubation were observed during the postoperative period until they were discharged from the hospital after 5 and 4 days, respectively.

Transmylohyoid endotracheal intubation provided effective and safe airway management while improving surgical conditions in these two cats with mandibular fractures. Other methods of management have already been described in cats. Tracheotomy is an alternative; however, it is a more invasive method and a high rate of complications has been reported (Guenther-Yenke & Rozanski 2007). Pharyngotomy has a high risk of potential complications owing to critical neurovascular structures in the proximity; laryngeal dysfunction and aspiration have been mentioned as possible long-term sequelae (Duke 1999). In addition, the small size of cats makes these techniques more challenging. This led us to use this modified approach of the previously described transmylohyoid technique in dogs (Soukup & Snyder 2015). Using a urinary catheter as an airway exchange catheter in a 'Seldinger-like' manner for reintubation allowed rapid and secure tube exchange while minimizing mandibular and laryngeal manipulation. Measuring depth of insertion, careful handling

and preventing catheter inhalation must be controlled to minimize risks.

This report demonstrates that transmylohyoid intubation is a feasible technique for airway management in procedures that require closure of the jaws in anaesthetized domestic cats.

Authors' contributions

SDB: clinical management, preparation and revision of manuscript. II: clinical supervision and critical revision of manuscript.

Conflict of interest statement

The authors declare no conflict of interest.

Sabina Diez Bernal & Isabelle Iff

Department of Anaesthesiology and Pain Therapy,
Vetsuisse Faculty, University of Bern, Bern, Switzerland
E-mail: sabina.diez@gmail.com (S Diez Bernal)

References

- Duke T (1999) Dental and maxillofacial surgery. In: *Manual of Small Animal Anaesthesia and Analgesia* (1st edn). Seymour C, Gleed R (eds). BSAVA, UK. pp. 147–153.
- Gadre KS, Kushte D (1992) Transmylohyoid oroendotracheal intubation: a novel method. *J Craniofac Surg* 3, 39–40.
- Guenther-Yenke CL, Rozanski EA (2007) Tracheostomy in cats: 23 cases (1998–2006). *J Feline Med Surg* 9, 451–457.
- Hartsfield SM, Gendreau CL, Smith CW et al. (1977) Endotracheal intubation by pharyngotomy. *J Am Anim Hosp Assoc* 13, 71–74.
- Soukup JW, Snyder CJ (2015) Transmylohyoid orotracheal intubation in surgical management of canine maxillofacial fractures: an alternative to pharyngotomy endotracheal intubation. *Vet Surg* 44, 432–436.

Received 29 November 2018; accepted 29 January 2019.

Available online 7 February 2019

<https://doi.org/10.1016/j.vaa.2019.01.007>

© 2019 Association of Veterinary Anaesthetists and American College of Veterinary Anesthesia and Analgesia. Published by Elsevier Ltd. All rights reserved.