



Surgical Management of Panfacial Fractures

Lexie Wang, MD¹ Thomas S. Lee, MD, FACS¹ Weitao Wang, MD² Dae Ik Yi, BS¹
Mofiyinfolu Sokoya, MD³ Yadranko Ducic, MD, FRCS(C), FACS³

¹ Department of Otolaryngology, Virginia Commonwealth University, Richmond, Virginia

² Department of Otolaryngology, University of Rochester, Rochester, New York

³ Otolaryngology and Facial Plastic Surgery Associates, Fort Worth, Texas

Address for correspondence Yadranko Ducic, MD, FRCS(C), FACS, Otolaryngology and Facial Plastic Surgery Associates, 923 Pennsylvania Avenue, Suite 100, Fort Worth, TX 76104 (e-mail: yducic@sbcglobal.net).

Facial Plast Surg 2019;35:565–577.

Abstract

Keywords

- ▶ panfacial
- ▶ trauma
- ▶ fractures
- ▶ Le Fort

The evaluation and management of a patient with panfacial fractures are multifaceted. Herein, we describe basic facial skeletal anatomy, considerations for airway securing, and common concurrent injuries. Finally, we discuss primary and secondary reconstructions of facial trauma including sequencing of repair, available landmarks, and the utility of intraoperative computed tomography imaging and virtual surgical planning with custom implants.

Evaluation and management of panfacial fractures can be a clinical challenge. While there is not a true definition of “panfacial” fractures, it is generally accepted to describe facial fractures that involve multiple subunits. Because of many fracture sites, it is critical to identify and predict current and future deficits and determine the best course of surgical and postoperative managements. These fractures are more difficult to treat than isolated facial fractures as there is limited normal framework to guide anatomic reduction. Additionally, oftentimes, these patients present with other significant trauma that must be managed concurrently. In this article, we review the anatomy of the facial skeleton with a focus on fracture patterns, diagnostic techniques, airway strategies, other injuries associated with panfacial fractures, and finally, management of panfacial fractures including initial and secondary reconstructions.

Anatomy and Diagnosis

The facial skeleton comprises multiple bony structures that are often split into thirds. The upper third consists of the frontal bone. The middle third consists of the orbit, zygoma, ethmoid, nose, and maxilla. Sometimes this is further divided into the upper midface (zygoma, nasoethmoid, and orbital regions) and the lower midface (maxilla and associated dentoalveolar segment). The lower third consists of the mandible. The facial

bones are supported by an extensive buttress system that can also be injured. As the facial skeleton acts as a protective structure for critical organs such as the brain and eye, restoration after injury is the key to maintain optimal function. The bony framework also provides the foundation for the overlying soft tissue and preserves the individuality of one's face. Proper reduction of facial fractures will maintain airway patency, promote optimal deglutition and speech, and restore preinjury facial aesthetics in terms of height, width, and projection.

Facial trauma is most commonly diagnosed on computed tomography (CT) imaging with some role for plain films; magnetic resonance imaging (MRI) is rarely used. Plain radiographs can be helpful for cephalometric preoperative planning if desired and for assessing the maxillomandibular subunit via panorex. Thin-cut (1 mm or less) CT scans of the facial skeleton, however, is the current standard in evaluating the entire facial skeleton. Three-dimensional (3D) reconstruction of CT scans can further aid in preoperative planning in panfacial trauma cases with poor reference points.

Airway Management

Securing the airway is the first step in the American College of Surgeons' Advanced Trauma Life Support protocol.¹ Managing the airway in patients with panfacial fractures is uniquely challenging because facial injuries often impede

routes of intubation. The primary means of securing the airway in most patients is orotracheal intubation by direct laryngoscopy; however, cricothyrotomy is indicated when vocal cords cannot be visualized via laryngoscopy. The rate of endotracheal intubation in patients with maxillofacial injury ranges from 2 to 6%. In a review of 1,025 facial fracture patients, 17 (1.7%) developed airway compromise requiring emergent interventions to secure an airway; most of these patients had bilateral pterygoid plate fractures resulting in posterior maxillary displacement.² While isolated mandibular fractures rarely cause airway compromise, high-energy trauma can result in atypical fracture patterns that can obstruct the airway. For example, Papadiochos et al described the “flared mandible” sign with inward displacement of the mandibular bodies and outward rotation at the angle leading to posterior displacement of symphysis and tongue.³ Furthermore, cervical neck injury must be considered in trauma patients, and if intubation is required, hyperextending the patient's neck should be avoided if there is concern for cervical spine (CS) fracture.

Intraoperative airway management of panfacial trauma patients is challenging due to competing space needs for airway maintenance and surgical access. Panfacial fractures involving the midface and lower face often require open reduction and rigid internal fixation⁴; however, orotracheal intubation may impede access to the facial skeleton and interferes with maxillomandibular fixation. The choice of intubation technique should be individually evaluated and requires an interdisciplinary assessment between surgeons and anesthesiologists. Alternatives to orotracheal intubation include nasotracheal intubation (NTI), submental intubation, and tracheostomy, each technique with advantages and limitations.

NTI is a preferred airway method during maxillomandibular fixation as it allows access to the oral cavity. However, NTI would not be appropriate for patients with complex midfacial fractures. NTI can directly interfere with reconstruction of naso-orbital ethmoid (NOE) fractures or any nasomaxillary vertical buttress fractures along the pyriform aperture.⁵ Additionally, NTI is contraindicated in fractures involving the cribriform plate as it increases the risk of complications including cerebrospinal fluid leak and inadvertent placement of the endotracheal tube through the skull base.⁶

Another common technique for airway control in patients with panfacial fractures is tracheostomy as it does not interfere with surgical access to the face.⁷ Although tracheostomy is secure and used extensively in reconstructive surgery, it is associated with a significant number of intraoperative and postoperative complications at a reported rate of 14 to 45%.^{8,9} These complications include hemorrhage, infection, damage to laryngeal nerves, tracheal stenosis, tracheomalacia, pneumonia, and aspiration.^{10–12} Thus, tracheostomy is usually reserved for patients who will require a prolonged period of airway control, long-term ventilatory support, or those with acute airway obstruction.¹³

Submental intubation is another alternative to orotracheal intubation developed by Hernández Altemir in 1986 to decrease morbidity caused by tracheostomy in patients with panfacial fractures.¹⁴ Patients are initially orotracheally intubated, and

then the tube is passed through the anterior floor of mouth and reconnected to the ventilator. This allows access to the lower two-thirds of the face without interference.¹⁵ Submental intubation appears to have lower morbidity and better outcomes when compared with tracheostomy. A retrospective study by Kita et al showed that 25 submentally intubated trauma patients had no severe perioperative or long-term complications, whereas 10 tracheostomy patients had major complications (subcutaneous emphysema, granulation formation, and hemorrhage) with cosmetically concerning scars.¹⁶ Rodrigues et al also reported submental intubation has lower complication rates, requires less time, and costs less than tracheostomy.¹⁷ In a prospective study by Shetty et al, all 10 submentally intubated patients did not have intraoperative complications, and motor or sensory deficits, superficial infections, and hypertrophic scarring were not found in all patients up to 6 months postoperatively.⁴ Submental intubation may be ideal in patients without severe airway swelling who can safely be extubated after surgery without requiring prolonged postoperative ventilation support. There is, however, a learning curve to this technique, and when passing the endotracheal tube from the floor of mouth to the submental region, the airway is unstable until the tube is reconnected to the circuit. Thus, some surgeons who routinely perform tracheostomy with efficiency may avoid this technique if a patient presents with floor of mouth edema or poor cardiopulmonary reserve who may not tolerate apneic episodes (→Fig. 1A–D).

Which method of intubation to use in panfacial fracture patients remains a clinical challenge. Although there are various forms of airway management, each technique has advantages and disadvantages. Thus, it is essential to recognize the types of facial fractures in trauma patients including the need for maxillomandibular fixation to determine the best intubation method.

Concurrent Injuries

Nahum demonstrated the degrees of force required to fracture different facial bones with the frontal bones being the most resilient. The amount of force required to fracture all the three thirds ranges from 362 to 725 kg (800–1,600 lb).¹⁸ Thus, trauma that is high impact enough to induce a panfacial fracture pattern often results in concurrent injuries that can be life-threatening and should be prioritized. This can alter timing of facial fracture management and pose intraoperative challenges especially with positioning and exposure.

In a retrospective review of 437 trauma patients presenting at a tertiary care hospital over 2 years, 38 patients were identified with panfacial fractures. A total of 53% had concurrent injuries, the most common of which was intracranial hemorrhage/injury in seven patients (18%). This was followed by abdominal organ injury in six (16%), pneumothorax in five (13%), pulmonary contusions in five (13%), and CS fractures in five (13%).¹⁹ Mulligan and Mahabir examined International Classification of Diseases codes from the National Trauma Data Bank in a 4-year period and found that in patients who had at least two facial fractures (defined as mandible, nasal, orbital floor, malar/maxilla, and frontal/parietal), the prevalence of CS

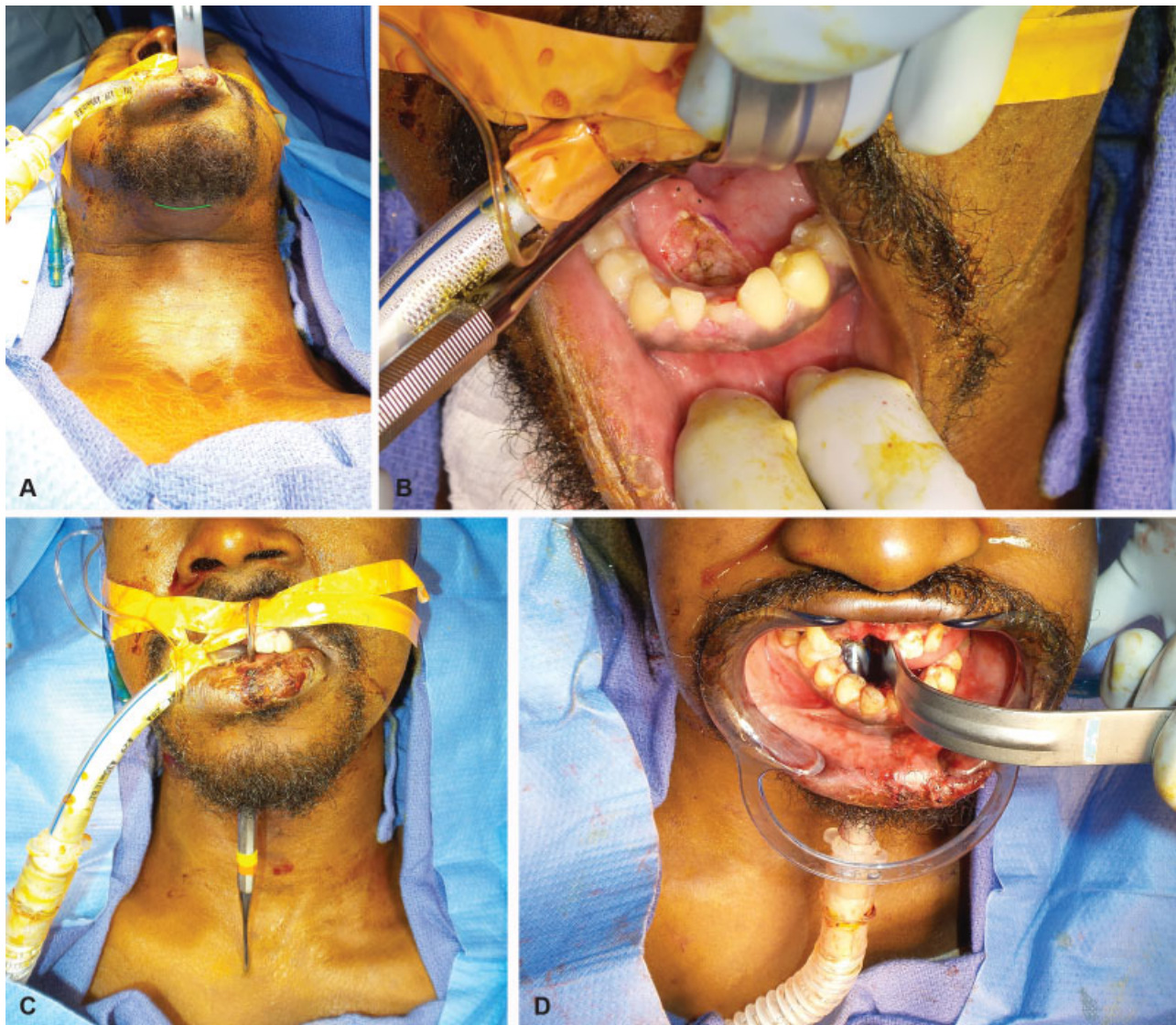

Fig. 1 (A–D) Submental intubation of a panfacial trauma patient. The submental incision should be placed just posterior to the inferior border of the mandible (A). The intraoral floor of mouth incision should also be placed just posterior to the lingual surface of the mandible and anterior to bilateral Wharton's ducts (B). The two incisions are then connected ensuring adequate space for passage of an endotracheal tube (C). The pilot balloon should be passed first through this tract, and then after appropriate preoxygenation, the endotracheal tube can be disconnected from the ventilator, passed through the same tract, and reconnected to the circuit with care to avoid accidental extubation during tube manipulation (D). The use of an armored endotracheal tube may be beneficial to avoid kinking of the endotracheal tube. End-tidal CO₂, appropriate tidal volumes, and bilateral breath sounds should be confirmed prior to securing the endotracheal tube with a suture along the skin incision site.

injury ranged from 7 to 10.8%, head injury from 65.5 to 88.7%, and both head and CS injuries from 5.8 to 10.1%. As one may expect, advancing cephalically on the face yielded a higher incidence of head injury from approximately 40% in mandible fractures up to approximately 80% in frontal fractures. However, there was not noted to be a difference in CS injury incidence between the different facial fracture distributions.²⁰

Management of any life-threatening injury should take precedence over surgery for facial fractures. In Tung et al's review of 1,025 patients presenting with facial fractures, 64 (6.2%) had associated life-threatening injuries, which they defined as severe enough to require invasive procedures such as chest tube placement, craniotomy, or massive blood transfusion. The most common associated injury was cerebral trauma in 21 of the 64 patients (32.8%).² Intracranial trauma

can range from a relatively benign process to something neurologically devastating. Minimizing further intracranial and neurologic deficits is critical. A multidisciplinary team that includes trauma surgeons, critical care specialists, and neurosurgeons can vastly assist in caring for these complicated patients. Discussion of intracranial trauma management is beyond the scope of this article; nevertheless, it is almost universally accepted that it is not safe to proceed with non-emergent surgeries in patients with unstable and/or elevated intracranial pressures (ICPs). In Alvi et al's review of "severely injured" (injury severity score ≥ 12) patients who had concurrent facial fractures, 24.5% patients required ICP monitoring.²¹ Surgeons need to be mindful that ICP monitoring probes can interfere with bicoronal scalp flap designs, cranial vault reduction, and pericranial flap development if needed.

Another consideration in patients with concurrent intracranial trauma is neurologic prognosis. It is difficult to predict how patients will recover as some who present with what appears to be devastating neurologic injuries make miraculous recoveries, especially young patients. Given that 11 of the 13 deaths in Alvi et al's patient population, however, were due to neurologic causes, this is a real concern to consider.²¹ Some surgeons will advocate for facial fracture repair if safe, regardless of neurologic prognosis, since secondary reconstruction is much more difficult with worse overall outcome once bony fusion has occurred with the bones displaced. Generally, it is best to avoid facial fracture repair if a patient has progressing intracranial bleed, and documentation of stabilized intracranial bleed with head imaging is preferred. Waiting for neurosurgical clearance if there is vertebral or carotid artery injuries is also recommended as these are associated with a high risk of neurologic morbidity (60%) and mortality (19–43%); additionally, these patients may require anticoagulation to prevent thrombus progression, which can affect ease of surgical repair.²²

CS injuries, including damage to the spinal cord, vertebrae, neck vasculature, and ligaments, are increasingly recognized in their association with facial fractures. Cognizance of preoperative CS injuries is especially important for the facial surgeon as manipulation of the head during reduction can exacerbate CS injuries. If possible, facial fracture repair should be deferred until the CS has been properly assessed and cleared. There are varying institutional protocols for clearing the CS that will not be addressed in this article. However, generally, the CS can be cleared on awake and sober patients who can provide a reliable exam.²³ In unconscious patients, one should be aware that a negative CT scan of the CS is inadequate to rule out ligamentous injury, and MRI may be required.¹⁹ If the CS cannot be cleared, then immobilization techniques should be utilized intraoperatively to avoid further injury to critical structures in the neck. Oftentimes, cervical collars impede access to the facial skeleton or airway. In-line stabilization techniques, such as strapping or taping the head to blocks, saline, or sandbags placed on either side of the head to secure the head down to the operating room table, should be exercised (→ Fig. 2).²³ It is imperative for

surgeons to be mindful to avoid manipulating the neck during surgery while retracting or attempting to reduce the bony fractures.

In summary, patients with panfacial fractures tend to present with concurrent injuries, some of which can be life-threatening. These other injuries can affect timing of facial trauma repair as well as intraoperative positioning and management. An astute reconstructive surgeon will collaborate with other physicians to ensure the safest care is delivered.

Facial Injury Management

Overview

When encountering a panfacial trauma patient, it is important to prioritize what needs to be addressed first, determine an order of a repair, and possibly leave any injuries that can be treated in a delayed, staged fashion.

First, it is best to identify injuries that will directly impact a patient's survival. The airway must be secured as discussed previously. Next, any significant bleeding should be managed. If the patient is stable, a CT angiography of the neck can determine vessel location; however, if the patient is too unstable, immediate neck exploration in an open fashion or endovascularly may be required. If there is carotid artery injury, a combination approach with a temporary endovascular balloon occlusion proximal to the injured segment can slow down bleeding enough to identify the site of vessel injury through an open incision, and one can determine if the vessel can be salvaged with sutures or stenting, or whether it must be tied off, with subsequent significant risk of stroke.

Once the airway and bleeding issues have been addressed, the facial fractures can be treated. Any concurrent soft tissue or skin injuries should be managed early as significant skin contracture in the next several days will grossly distort the tissue. If a patient is unable to tolerate prolonged general anesthesia, one can reapproximate the skin edges to cover exposed bone or critical neurovascular structures or place a temporary wound dressing with a plan for more definitive repair at the time of facial fracture reconstruction.

If a patient is stable enough to undergo general anesthesia, bony fractures should be reduced first as the bone positioning affects the position of the overlying soft tissue and skin. The following section will discuss facial fracture repair extensively. Once the facial fractures are reduced, soft tissue injuries can be treated. Soft tissue injuries that require early (less than 1 week) correction include near total eyelid defects, facial nerve repair after transection, parotid duct cannulation with repair, resuspension of detached medial or lateral canthi, and lacrimal duct repair and stenting. Finally, skin closure is performed with the goal of ensuring underlying bone, fixation hardware, major neurovascular structures, and other important soft tissue structures are covered and protected from the environment. If there is a sizable defect, the surgeon must decide if it should be reconstructed immediately or later. It is best to minimize extensive skin flap dissection as flap vascularity may be compromised and not immediately obvious in the trauma setting. Sometimes, it is best to close off the skin even if it causes gross distortion with a plan for staged reconstruction,

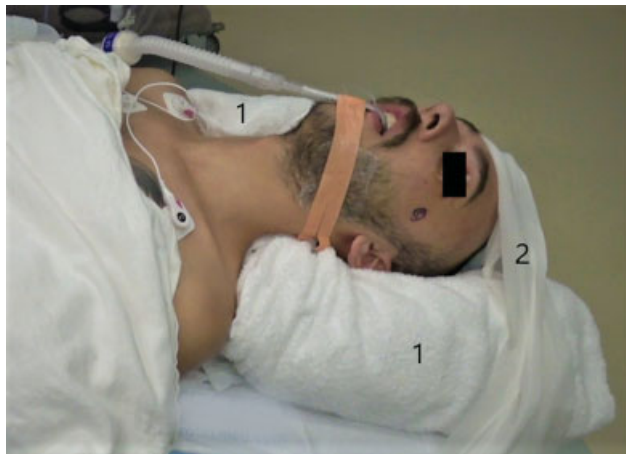

Fig. 2 An example of intraoperative cervical spine immobilization using large towel rolls and saline bags (1) on either side of the patient's neck, and the patient's head is taped to the operating table (2) for further immobilization.

as long as underlying bone, fixation hardware, and neurovascular structures are covered. If it is not possible to close the skin, a surgeon must decide if a temporary wound dressing can be safely applied or pursue regional or free flap reconstruction to provide adequate coverage. If regional or free flaps are used, it is best to harvest excess skin and soft tissue as there is a high risk of wound dehiscence or infection that may require future debridement, and the natural tissue contracture process will also result in flap bulk reduction (►Fig. 3A–G). Three to six months postoperatively, any excess bulk can be safely removed for optimal skin contour. Sometimes soft tissue repair cannot be performed immediately, such as if there is ongoing wound infection, patient instability under anesthesia, or more sophisticated techniques such as microsurgery are required by another surgeon. In such a scenario, critical structures such as transected nerve endings should be marked with color sutures to help identification during subsequent surgery.

Facial Skeleton Management

In this section, we will discuss issues concerning fracture repair. Ideally, the surgeon should have extensive experience in treating isolated fractures of different facial subunits with an intimate understanding of natural facial contours. Panfacial fractures pose additional challenges due to the multitude of subunits involved and increasingly poor reliability of useful landmarks (►Fig. 4A, B). The surgeon must first identify all the facial fractures and determine which fractures will require fixation. Not all fractures require plating, and hardware should only be used to fixate critical fractures as every hardware poses a risk of future complication. One should focus on restoring (1) premorbid occlusion, (2) the major buttresses of the face before considering the minor buttresses for additional stability if needed (►Fig. 4A), and (3) premorbid facial width and height to provide function and facial symmetry. Similarly, Curtis and Horswell stated that the key areas to restore are the zygomaticosphenoid suture, maxillary arch, orbital frame and volume, and buttress support system.²⁴ Prior to surgery, the surgeon should have a clear plan on which fractures will be fixated. Potential need for bone graft harvesting and additional reconstruction involving soft tissue or skin should be anticipated, and consent should be obtained for all possible procedures.

There are several guiding principles to approaching a panfacial trauma case. All fractures that require fixation are exposed first. Next, rudimentary bone reduction is performed by mobilizing grossly depressed segments along the major facial buttresses. By starting out with a fracture site with the most reliable landmarks and least comminution, one can minimize error in bone reduction being transferred to adjacent fracture sites. Prior to rigid fixation, premorbid occlusion must be re-established using maxillomandibular fixation. In cases where bilateral condylar fractures are significantly displaced, addressing at least one side before reducing the other mandible fractures is preferred to re-establish the proper mandible height. Other authors recommend disimpaction and fixation of palatal fractures to use the maxillary dental arch as a template for the mandibular dental arch to maintain proper facial width.^{21,25}

To confirm proper reduction, normal bony landmarks and subtle cues from fracture alignment should be respected. During maxillomandibular fixation, preexisting dental wear facets can confirm proper occlusion. Similarly, the inferior border of the mandible can be a useful guide along the parasymphysis and body. Along the angle, visualization of the posterior and inferior borders can be achieved with an external approach but will be difficult with an intraoral approach. In this case, the external oblique ridge of the mandible can be used as a visual guide for fracture alignment. It is important to ensure that the molars maintain good contact and manual pressure is applied along the inferior border of the mandible during plating of angle fractures, where the condyle segment is prone to rotating and drifting away, creating potential for a cross bite or open bite deformity.

The lateral curvature of the maxilla serves as a useful landmark for the zygomaticomaxillary complex (ZMC) fracture site along the lateral vertical buttress (►Fig. 4B). Superiorly, the lateral orbital rim can serve as a landmark for the zygomaticofrontal suture line that is commonly involved in a ZMC fracture. Along the medial vertical buttress, the pyriform aperture curvature is a useful landmark and can be fully exposed from the nasal floor to the nasal bone. One can confirm proper reduction of both the medial and lateral buttresses with a contiguous and reduced infraorbital rim.

Once the medial and lateral vertical buttress fractures are corrected, orbital floor repair can be done at this time or the surgeon may opt to stage the orbital floor reconstruction in a delayed fashion once orbital edema has resolved. With NOE fractures, if the medial canthus is disrupted, it is best to reattach the medial canthus at the time of bony fracture repair as the medial canthus can undergo undesirable scar contracture that is difficult to correct. Instead of performing transnasal wiring, which can cause problematic nasal crusting and has suboptimal control with placement, the senior authors prefer to resuspend the medial canthus with 3–0 Prolene to a hole from a miniplate or through a bone tunnel (►Fig. 5) or use a miniature Mitek screw to secure the medial canthus. Lateral canthus detachment can be corrected in a similar fashion (►Fig. 6). If there is septal or nasal bone fracture that requires correction, limited septoplasty or nasal fracture reduction should be performed prior to lacrimal duct stenting to minimize interference from the lacrimal stent occupying the nasal cavity. If there is concern for lacrimal duct injury as is commonly seen in NOE fractures, lacrimal duct stenting should be performed if the medial canthal skin is not grossly infected or devascularized (►Fig. 7A, B). If, however, there is significant disruption to the medial canthus and surrounding eyelid tissue, one can defer lacrimal stenting with a plan for a staged dacryocystorhinostomy once the tissue quality has improved to avoid wound breakdown and nasal fistula formation.

In the upper face, the superior orbital rim can be exposed to re-establish the natural contour of the frontal bone, especially if the anterior table of the frontal sinus is fractured (►Fig. 4B). If frontal sinus obliteration or cranialization is planned, at the time of bicoronal flap development, an

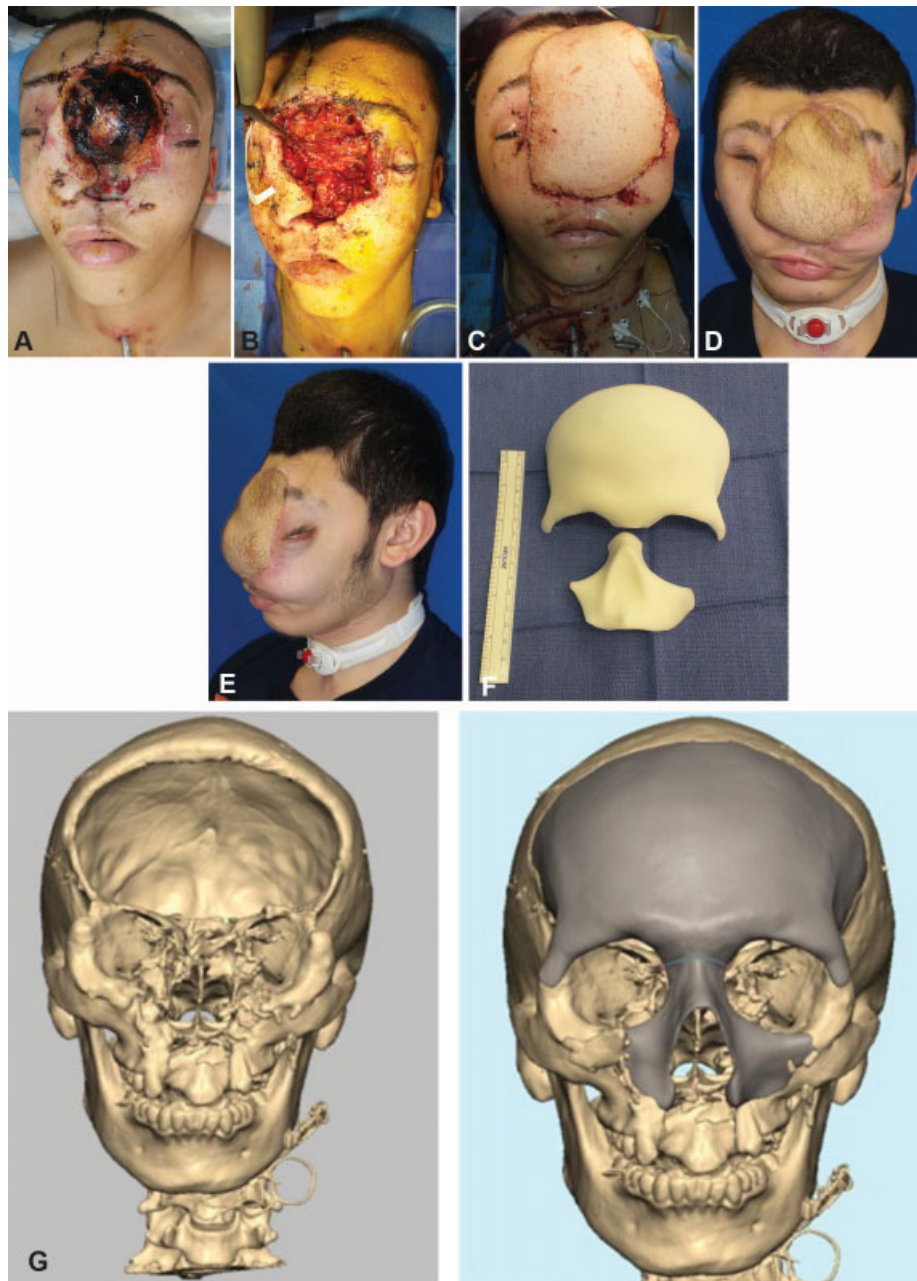


Fig. 3 (A) This patient suffered a shotgun blast injury to the midface and skull base with a full-thickness defect involving the entire midface with exposed devitalized frontal lobe (1) along with left globe rupture (2) that required enucleation. Surgery was delayed for about 2 weeks to assess for neurologic prognosis. After extensive discussion, reconstructive procedures ensued. (B) In coordination with neurosurgery, an extensive amount of frontal lobe (1) and anterior skull base was debrided until healthy bleeding tissue was encountered. After left eye enucleation, periorbital soft tissue (2) was used as a sling to support the anterior skull base and separate it from the nasal cavity. Due to the injury pattern, a vascularized pericranial flap was not available and bone grafting was not a reasonable option due to extensive infection present. (C) Due to the full-thickness skin/bone defect overlying the exposed frontal lobe and the tenuous nature of the injured soft tissue, a decision was made to perform a large anterolateral thigh free flap to seal off the skull base and midface defect without performing bone reconstruction at this time. (D, E) The patient had an impressive neurologic recovery. Once the brain swelling had resolved, it left a severe deformity from the bilateral frontal craniectomy and midface bone defect. The patient had hard time wearing a helmet to protect his brain. (F, G, H) The patient underwent a custom implant placement as he could not wear the helmet for protection consistently. The implant was created from his CT imaging and used to recreate the cranial vault and the midline midface defect. The implant is made of Medpor porous polyethylene material to encourage tissue ingrowth. The hardware was placed through the previous bicoronal incision without an intraoral approach to minimize the risk of contamination or hardware extrusion. The implant was sandwiched between the ALT flap. (I) After waiting about 6 months after successful cranial vault and midfacial implant placement, bilateral medial canthopexy (3) was performed and secured to the underlying Medpor implant. (1) A layer of well-vascularized tissue covering the underlying cranial vault implant can be seen. An existing skin incision between the native skin and the ALT flap was utilized for surgical access. The ALT flap (2) was reflected inferiorly and remained pedicled along the inferior aspect for blood supply. (J, K) Along with bilateral medial canthopexy, the patient also underwent vestibular stenosis repair to recreate the nasal airway with careful attention to avoid hardware exposure to the nasal mucosal lining. He had a surprisingly normal nasal cavity with inferior turbinates and skull base intact and only missing the anterior septum. Currently, he is awaiting additional flap debulking with total nasal reconstruction using an osteocutaneous radial forearm free flap with rib cartilage. For the final result, a left eye prosthesis is planned. ALT, anterolateral thigh.

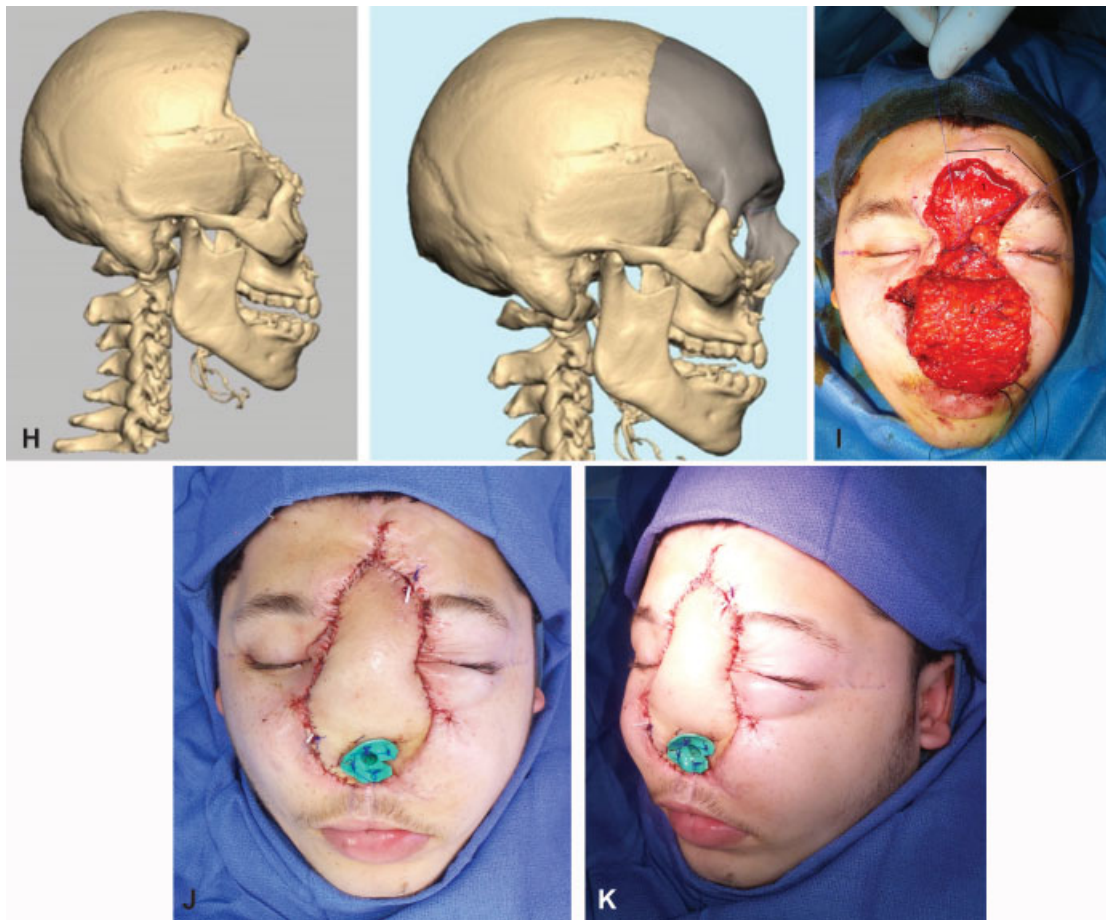


Fig. 3 (Continued)

anteriorly based pericranial flap should be elevated with care to preserve its blood supply from the supratrochlear and supraorbital vessels. If frontal sinus obliteration, cranialization, or anterior skull base repair is required, it should be done prior to facial fracture repair. Next, the frontal sinus and the superior orbital rim fractures are reduced and plated, and finally, the cranial vault fracture is fixated prior to scalp closure (► **Fig. 8A–E**).

There is ongoing controversy regarding the sequence of repair. In reality, a surgeon must stay flexible and may use a combination of sequences as each patient will have a unique pattern of injury. There are multiple cited approaches to treating panfacial fractures that generally fall into “top-down” or “bottom-up” direction. The “top-down” technique begins the reduction at the calvarium and upper face and moves down the midface addressing the mandible last. The “bottom-up” technique begins with re-establishing the maxillomandibular occlusion, completing the mandible fractures, followed by midfacial fractures and building upward to the superior orbital rim, frontal sinus, and cranial vault (► **Fig. 8A–E**). “Outside-in” refers to starting out in the periphery and moving medially, for example, beginning with ZMC fractures along the lateral buttress and advancing toward the NOE segment along the medial buttress. “Inside-out” implies the opposite.

The rarity and varied fracture patterns make outcomes of different panfacial fracture approaches difficult to analyze. Degala et al prospectively compared two common treatment sequences with 11 patients total (6 in the “top-down” group and 5 in the “bottom-up” group) and found that all patients were able to obtain normal occlusion, and there was no statistically significant difference in mouth opening, facial symmetry, or overall treatment outcome between the two groups.²⁵ The ideal approach should be individualized. The senior authors use a combination of these approaches and start with less comminuted segments with more visible reference points to ensure proper reduction and avoid compounding error by fixation of subsequent more comminuted and difficult fracture segments.

Perioperative Imaging

Intraoperative CT imaging has been gaining popularity in the repair of facial fractures. The O-arm allows CT images to be obtained immediately before and after plating to ensure proper placement. In addition, intraoperative CT data can be uploaded to a neuronavigation system to provide updated anatomic information, which can be useful in complex skull base trauma cases. The benefit of intraoperative CT imaging is surgeons have the opportunity to review and adjust plates, potentially avoiding revision surgeries in cases of improper

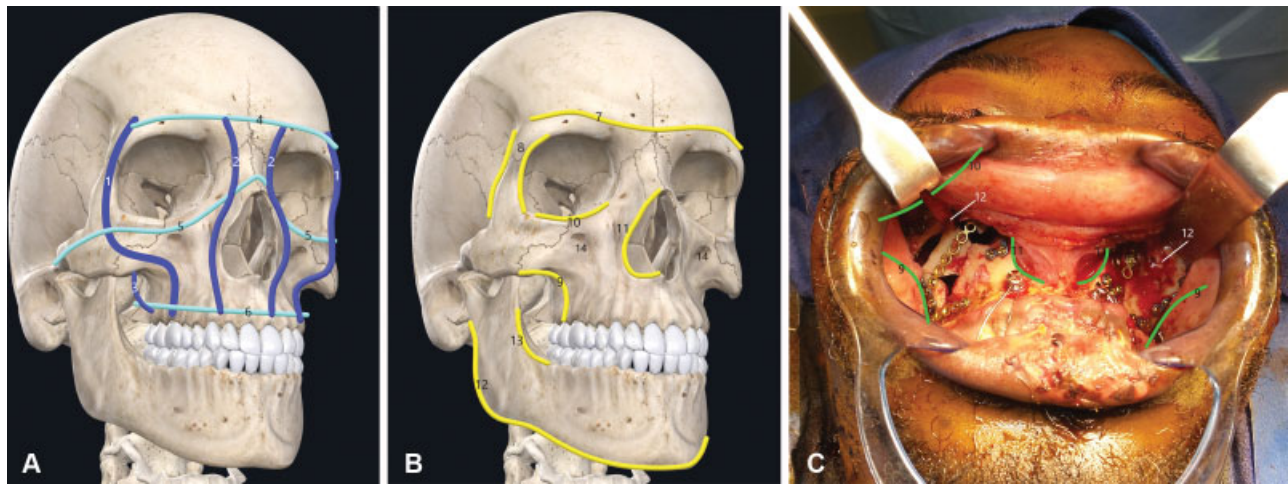


Fig. 4 (A) Major buttresses oriented vertically are highlighted in darker blue, while minor buttresses oriented in the horizontal plane are highlighted in lighter blue. The numbers describe the following structures: (1) Lateral maxillary vertical buttress (zygomaticomaxillary) can be subdivided into zygomaticofrontal and zygomaticomaxillary buttresses, separated by the infraorbital rim and the zygomatic arch. (2) Medial maxillary vertical buttress (nasomaxillary) can be subdivided into nasofrontal and nasomaxillary buttresses separated by the infraorbital rim. (3) Posterior maxillary vertical buttress (pterygomaxillary) consists of bilateral pterygoid plates. This fracture is not accessible for plating. Bilateral pterygoid plate fractures are associated with palate mobility as observed in Le Fort fractures. (4) Superior transverse buttress (frontal bar). (5) Middle transverse maxillary buttress consists of infraorbital rim and zygomatic arch. (6) Inferior transverse maxillary buttress consists of hard palate and maxillary alveolus. (B) When correcting fractures that exist along major and minor buttresses, commonly used landmarks to confirm proper bony reduction are highlighted in yellow lines. (7) The frontal bar follows a predictable curved contour along the superior orbital rim and the frontal bone. (8) The lateral orbital rim is helpful for fractures that occur along the zygomaticofrontal suture line. (9) The natural curvature of the maxilla is an important landmark used to restore the zygomaticomaxillary buttress. (10) The infraorbital rim contour connects the medial and the lateral buttresses and is located superior to the infraorbital nerve (14). (11) The natural curve along the pyriform aperture is helpful in reducing the medial buttress. (12) The inferior border of the mandible is a useful landmark to confirm proper reduction of body, symphyseal, and parasymphysal fractures of the mandible. However, visualization of the inferior border of mandible at the angle can be challenging through an intraoral approach. As such, the external oblique ridge of mandible (13) can be used as an adjunct landmark. If an external approach to the mandible is used, the inferior and posterior borders of mandible (12) remain a reliable landmark in angle and subcondylar fracture repair. (C) This patient suffered bilateral Le Fort II fractures with a mobile palate, concurrent type 1 NOE fractures that required rigid fixation using a modified Lynch incision, and left-sided total orbital floor blowout with diplopia requiring orbital implant placement. Green lines show intraoperative bony landmarks used to ensure proper bone reduction. The numbers correspond to structures from (B). Plates are shown to transverse fracture lines to provide proper rigid fixation. NOE, naso-orbital ethmoid.

hardware alignment. This technology may be especially useful in orbital floor implant positioning, condyle fractures with gross displacement out of the glenoid fossa, and skull base trauma cases. Borad et al demonstrated a change in management in 44% of cases when the O-arm was utilized for orbital fracture repair in a retrospective study of 101 patients.²⁶ Cuddy et al reviewed 161 patients and found the overall intraoperative CT-directed revision rate was 28% (by fracture subsite: 31% orbital, 24% ZMC, 8% Le Fort I, 23% Le Fort II and III, 23% NOE, 13% mandible, and 0% frontal sinus).²⁷ Routine use of intraoperative imaging depends on the availability of the O-arm. A downside is that the patient is exposed to radiation from CT imaging, and surgeons must wear lead during surgery. If intraoperative CT imaging is unavailable, postoperative scans may be obtained to verify fracture reduction and may be useful for medicolegal reasons.

Postoperative Care

Routine use of postoperative antibiotics is not indicated unless there is existing infection prior to operative repair according to a literature review by Munding et al.²⁸ Nonetheless, it is wise to consider antibiotics in the setting of grossly dirty wounds especially if critical neurovascular

structures along the skull base or neck were involved in the injury. Mastication should be limited with a soft diet for 6 to 8 weeks postoperatively to avoid introducing force onto the healing maxillomandibular subunit. Long-term rehabilitation should include jaw opening exercises, especially if the condyles were injured, to avoid temporomandibular joint (TMJ) scarring. Whenever possible, one should avoid prolonged rigid maxillomandibular fixation, especially if mandible and maxilla fractures were addressed via open approach, given associated complications such as fatal aspiration risk after vomiting, poor patient satisfaction, and difficulty with nutrition.

Secondary Reconstruction

Delayed repair of panfacial fractures occurs either due to severity of other injuries or lack of available surgical expertise at the time of injury. These patients can have debilitating sequelae including recurrent infections, ocular symptoms such as enophthalmos and epiphora, changes involving the jaw such as malocclusion and trismus, and facial flattening or asymmetric widening. In He et al's review of 33 patients who presented at least 4 weeks out from injury with panfacial fractures, all 33 had malocclusion, 20 (60.6%) had limitation

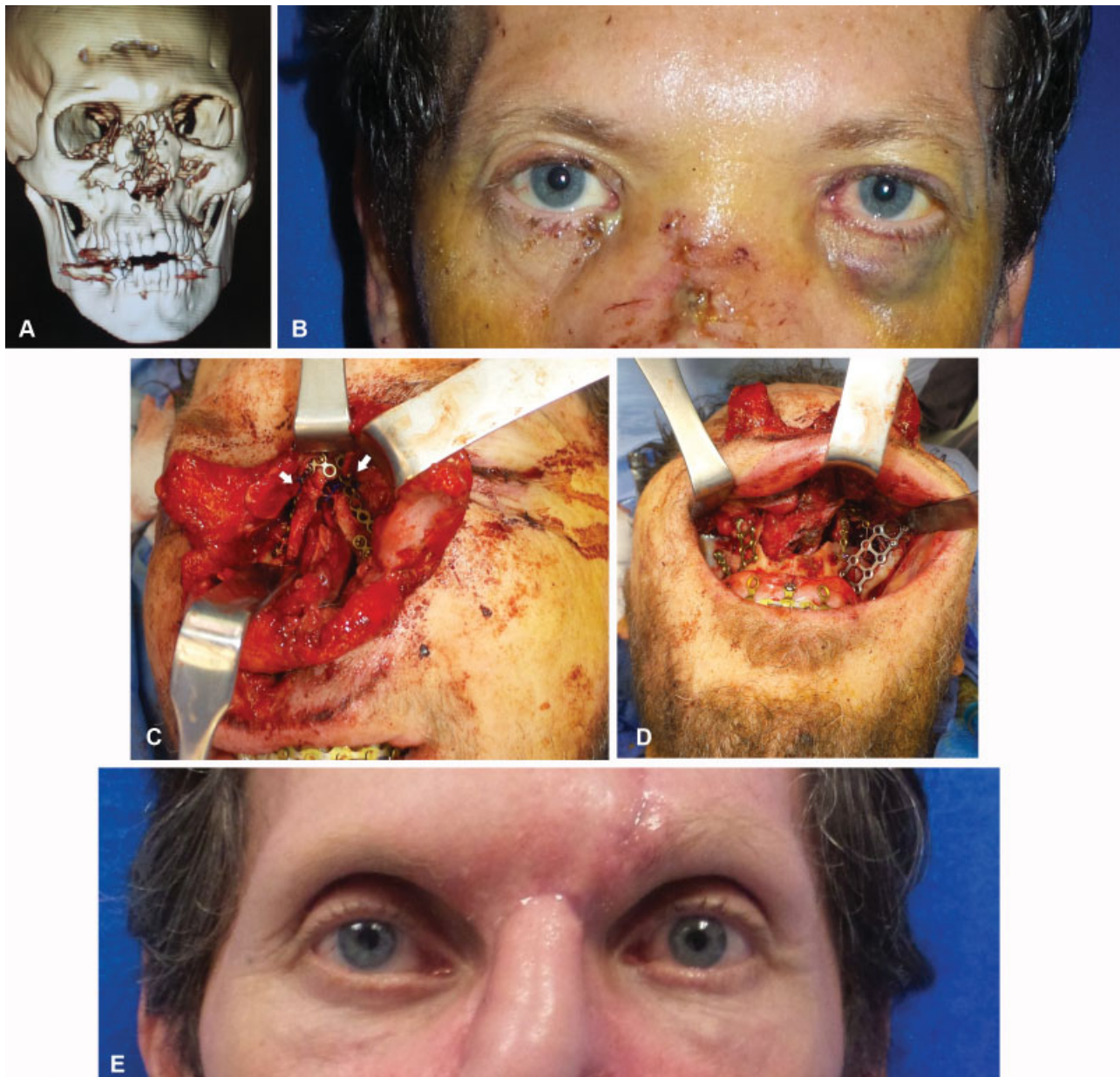

Fig. 5 (A–E) Medial canthoplasty in a patient with bilateral type 3 NOE fractures and bilateral Le Fort fractures after a firework exploded on his nose. (A) 3D reconstruction of CT scan demonstrating the extent and comminution of the patient's injuries. (B) Preoperative imaging of patient with obvious telecanthus and nasal widening/flattening. (C) Using a preexisting nasal laceration and bilateral maxillary vestibular approach, the NOE fractures were fixated with long spanning plates from the frontal bar to the medial buttress below. White arrows highlight bilateral medial canthopexy sutures used to reattach bilateral medial canthus tendons to the miniplate holes at the desired location. (D) Bilateral Le Fort II fractures involving bilateral medial and lateral buttresses are plated after the patient was brought into maxillomandibular fixation. (E) Postoperative view shows correction of telecanthus with improvement in medial canthus positioning. Due to extensive nasal skin injuries with concern for bone graft or hardware extrusion, the saddle nose deformity along the upper two-thirds was not corrected immediately. Instead, he underwent nasal reconstruction with a paramedian forehead flap and a dorsal onlay rib cartilage graft once his nasal skin envelope had healed. NOE, naso-orbital ethmoid.

in mouth opening with 5 (15.2%) patients with true TMJ ankylosis defined as < 15 mm opening, and 12 (36.4%) had enophthalmos or hypoglobus.²⁹ Unfortunately, once outside a window of about 2 to 3 weeks from injury, bone malunion and soft tissue atrophy begins, which can make secondary reconstruction even more challenging.

Virtual Surgical Planning

Addressing panfacial fractures secondarily can be difficult and may require additional osteotomies, grafts, and custom

patient-specific implants to obtain optimal results. One of the innovations in management of craniomaxillofacial trauma in recent years is virtual surgical planning (VSP). Kupfer et al described the advantages that VSP bring to management of ballistic trauma, including free manipulation of fracture fragments into proper reduction as well as formulation of prebent custom plates to span specific fracture segments. This improved accuracy of the final reduction and reduced operative times.³⁰ In cases where a significant amount of bone is missing, importing preexisting scans if available can

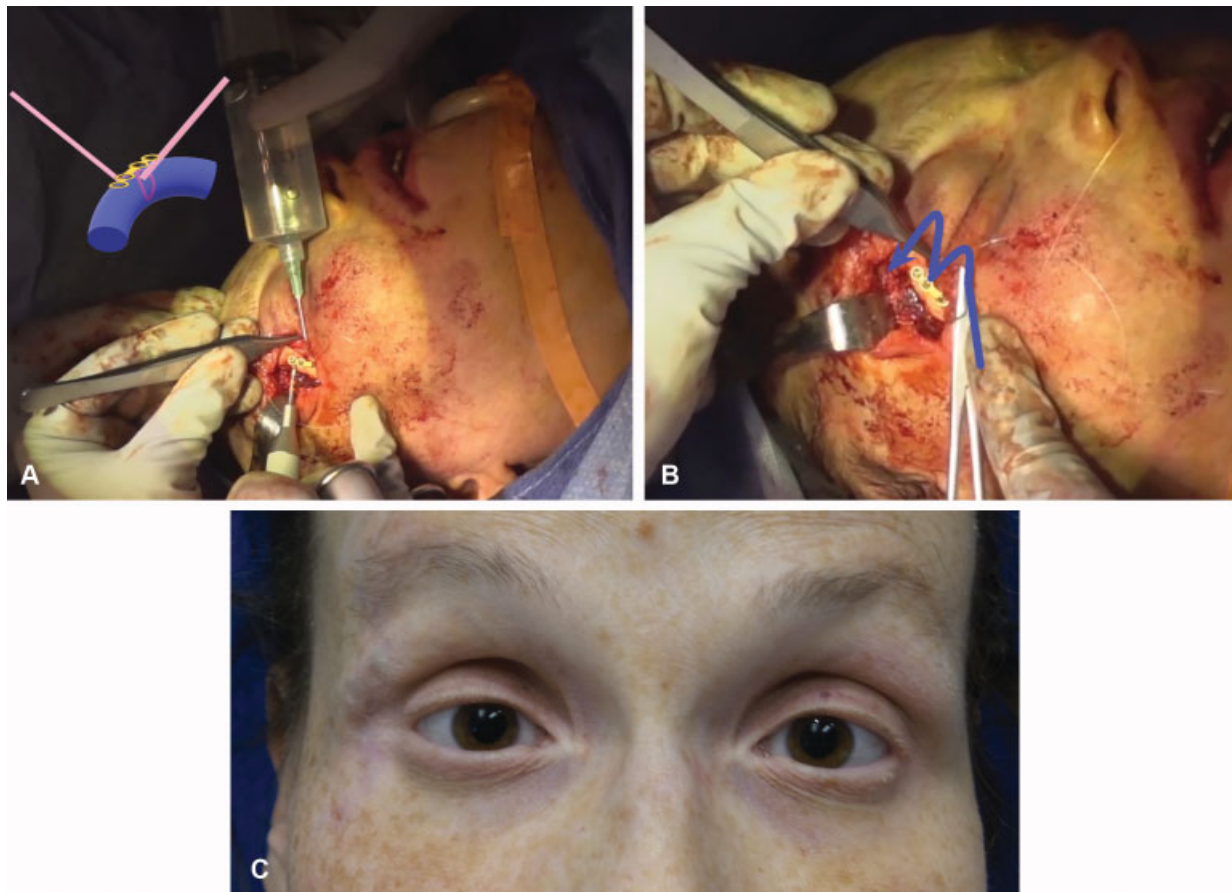


Fig. 6 (A–C) Lateral canthopexy technique. Typically, lateral canthopexy can be performed by reattaching the lateral canthus tendon to the periosteum at Whitnall's tubercle. However, this patient suffered severe comminution of the lateral orbital rim and no reliable periosteum was available. In addition, there was no reliable bone stock where a Mitek screw could be placed and no plate hole to hold a suture. (A) As such, a bone tunnel (pink lines) was created in the anatomically correct position for the lateral canthus (by using the noninjured side as a reference), shown here under the miniplate. (B) A 4–0 Nylon suture is used to resuspend the lateral canthus along its inferior and superior limbs. (C) Six-month postoperative image of the patient demonstrating good symmetry and position of bilateral lateral canthi. The laceration that was used to access the lateral orbital rim had healed well with good cosmesis.

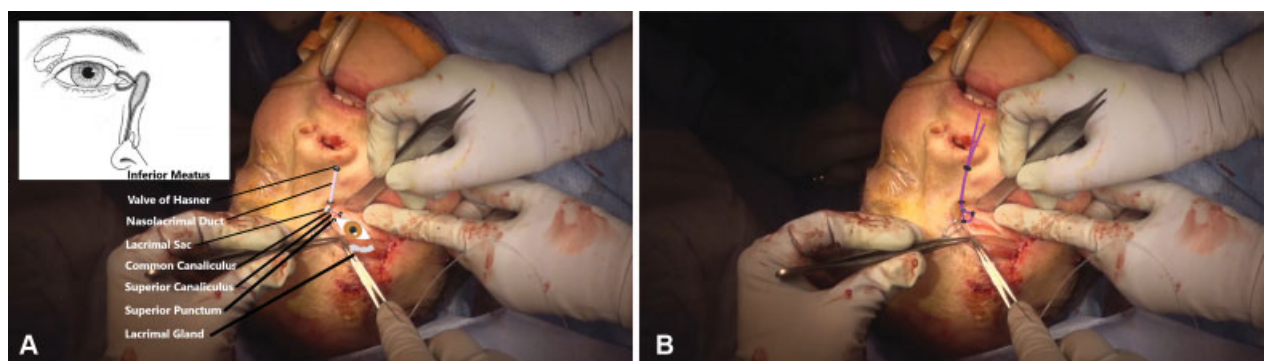


Fig. 7 (A, B) Lacrimal duct stenting may be necessary with NOE fractures and severe disruption of the lacrimal bone. (A) Both ends of the Crawford stent can be passed through the superior and inferior puncta and into the lacrimal system. Black holes represent openings that the stent must pass in sequence to exit through the valve of Hasner located along the inferior meatus intranasally. (B) The ends of stents can then be tied together and secured with a suture for easy identification and subsequent removal at a later date. NOE, naso-orbital ethmoid.

be useful for anticipated bony grafting or free tissue transfer. Formulation of cutting guides can decrease intraoperative time and increase accuracy. In situations of massive facial soft tissue and bony avulsion where even a face transplant is to be considered, a custom implant can be designed to provide support as long as the implant can be sealed safely

inside well-vascularized tissue and is separated from the nasal or oral mucosal lining to minimize infection and extrusion (► Fig. 3E).

Updating diagnostic imaging is imperative, and 3D reconstruction of CT scans are especially useful in this situation for VSP and general planning purposes.^{29,31} Some surgeons also

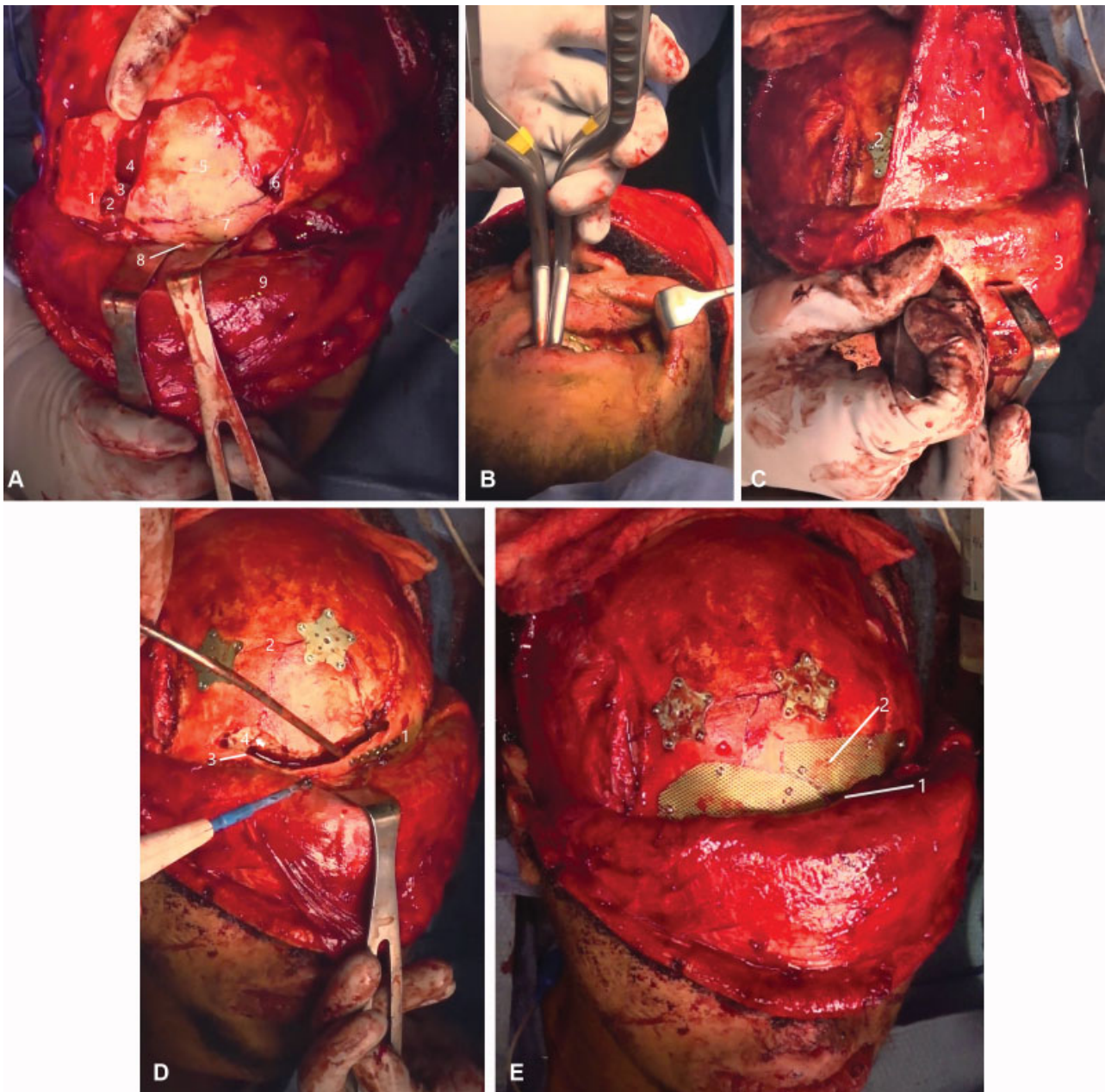


Fig. 8 (A) This particular patient had fallen out of a building and suffered extensive skull base fractures including cranial vault fracture, bilateral frontal sinus fracture involving anterior and posterior tables without CSF leak, and bilateral Le Fort II and III fractures. After the midfacial fractures were exposed, a bicoronal incision was used to access the upper face and the cranial vault. (1) Anterior table of right frontal sinus, (2) frontal sinus, (3) posterior table of frontal sinus, (4) dura of frontal lobe, (5) frontal bone fracture, (6) left frontal sinus with anterior table defect, (7) left supraorbital rim, (8) nasofrontal suture line, and (9) pericranial flap raised and left attached to the bicoronal skin flap. (B) Rowe maxillary disimpaction forceps are used to lift the maxillary segment to re-establish occlusion prior to maxillomandibular fixation. (C) Bilateral maxillary fractures were plated using maxillary vestibular approach. We performed a “bottom-up” repair by following with the lateral orbital rims, the superior orbital rim, and finally, the cranial vault was plated. (1) Demonstrates the pericranial flap that will be used to obliterate the frontal sinus. (2) Cranial vault plate is seen. (3) Bicoronal skin flap. (D) Frontal sinus obliteration is completed after stripping all the mucosal lining and drilling down the bone to prevent mucocoele formation. Note the pearly white bone appearance after aggressive mucosal removal. As the posterior table (4) was largely intact, frontal sinus obliteration was performed instead of cranialization. (1) Plate stabilizing the supraorbital rim. (2) The depressed cranial vault fracture along the frontal bone has been reduced and fixated with plates. (3) Anterior table of the frontal sinus along the frontal bar/supraorbital rim. (4) Well-reduced posterior table fracture highlighted with a white arrow. (E) Frontal sinus obliteration is performed by tucking the pericranial flap (1) in an accordion fashion. A 2- to 2.5-mm gap is left along the inferior bone margin of the frontal sinus opening to preserve the pericranial flap blood supply. Titanium mesh (2) is used to recreate the natural contour of the anterior table of frontal sinus. CSF, cerebrospinal fluid.

advocate for creating dental impressions if re-establishment of occlusion or mandibular and maxillary arches is necessary. This time-consuming task can be quickly addressed with VSP and prefabricated splints.

Mild malocclusion can be addressed nonoperatively with elastics or orthodontics. Severe or refractory cases will require orthognathic surgery. In He et al's population, all patients required Le Fort I osteotomy to correct

malocclusion. This group was able to obtain good results with all but two patients restoring to correct occlusion. These two were patients who were unable to have preoperative dental impressions made due to severe trismus.²⁹ Newer reports utilized VSP in secondary repairs of malocclusion. Thor described using VSP and patient-specific implants with cutting guides for precise osteotomies in secondary reconstructive trauma surgery.³²

Secondary orbital wall repair can be difficult especially if any scarring has occurred. Of the 12 patients presenting with enophthalmos in He et al's review, 6 required orbital wall reconstruction with either bone graft or porous polyethylene sheets. Three patients did not receive any kind of orbital wall reconstruction and remained enophthalmic, but the remaining nine patients were able to restore to normal globe position.²⁹ Khader et al recommended complete subperiosteal dissection in the orbit when attempting secondary reconstruction to ensure there is no tethering of scar tissue.³¹ A patient-specific implant can be helpful in these challenging orbital trauma cases. Mirroring the unaffected side in cases of severely comminuted orbits can offer symmetric reconstruction. A case of reconstructing a large orbital floor defect with a custom implant from VSP and image navigation has been described.³³ Kärkkäinen et al also reported 15 patients who underwent repair of primary orbital fractures with patient-specific implants without any revisions or complications.³⁴ Their study demonstrates the accuracy and reliability of custom-fabricated implants. Cost analysis is needed for routine use, but custom implants may play a useful role in obtaining optimal results in complex facial trauma cases.

Conclusion

Panfacial fracture management can be complicated. A thorough understanding of normal anatomy is key for restoration of function. As in all trauma cases, establishing a safe and secure airway is the first priority. Given the intimacy of the facial skeleton and associated soft tissue with the upper airway, a surgeon must be aware of a variety of techniques for securing an airway including NTI, orotracheal intubation, submental intubation, and tracheostomy. Due to the nature of injury, patients with panfacial fractures often present with concurrent life-threatening injuries, such as CS fracture, carotid/vertebral artery injuries, or intracranial bleed that can affect timing and ease of repair. Sequencing of operative repair of panfacial fractures can be approached in a logical fashion depending on the individual's fracture pattern. Bony fractures should be addressed before correcting nonlife-threatening soft tissue or skin injuries that can be repaired concurrently or in a staged fashion to avoid serious post-injury complications. Intraoperative imaging can confirm optimal reduction and fixation of fracture fragments if available. Finally, treatment of secondary panfacial fractures can be particularly challenging due to variable bone resorption and the state of the soft tissue envelope. Virtual surgical planning with custom patient implants is becoming more popular as it offers increased precision to obtain ideal functional and cosmetic results.

Funding

No financial support was received.

Conflicts of Interest

None.

References

- Chapleau W, Al-khatib J, Haskin D, et al; ATLS Subcommittee; American College of Surgeons' Committee on Trauma; International ATLS working group. Advanced trauma life support (ATLS®): the ninth edition. *J Trauma Acute Care Surg* 2013;74(05):1363–1366
- Tung TC, Tseng WS, Chen CT, Lai JP, Chen YR. Acute life-threatening injuries in facial fracture patients: a review of 1,025 patients. *J Trauma* 2000;49(03):420–424
- Papadiochos I, Goutzanis L, Petsinis V. Flail mandible and immediate airway management: traumatic detachment of mandibular lingual cortex results in obstructive dyspnea and severe odynophagia. *J Craniofac Surg* 2017;28(05):1311–1314
- Shetty PM, Yadav SK, Upadya M. Submental intubation in patients with panfacial fractures: a prospective study. *Indian J Anaesth* 2011;55(03):299–304
- Caron G, Paquin R, Lessard MR, Trépanier CA, Landry PE. Submental endotracheal intubation: an alternative to tracheotomy in patients with midfacial and panfacial fractures. *J Trauma* 2000;48(02):235–240
- Muzzi DA, Losasso TJ, Cucchiara RF. Complication from a nasopharyngeal airway in a patient with a basilar skull fracture. *Anesthesiology* 1991;74(02):366–368
- Demas PN, Sotereanos GC. The use of tracheotomy in oral and maxillofacial surgery. *J Oral Maxillofac Surg* 1988;46(06):483–486
- Wood DE, Mathisen DJ. Late complications of tracheotomy. *Clin Chest Med* 1991;12(03):597–609
- Schütz P, Hamed HH. Submental intubation versus tracheostomy in maxillofacial trauma patients. *J Oral Maxillofac Surg* 2008;66(07):1404–1409
- Das P, Zhu H, Shah RK, Roberson DW, Berry J, Skinner ML. Tracheotomy-related catastrophic events: results of a national survey. *Laryngoscope* 2012;122(01):30–37
- Goldenberg D, Golz A, Netzer A, Joachims HZ. Tracheotomy: changing indications and a review of 1,130 cases. *J Otolaryngol* 2002;31(04):211–215
- Nwoku AL, Al-Balawi SA, Al-Zahrani SA. A modified method of submental oroendotracheal intubation. *Saudi Med J* 2002;23(01):73–76
- O'Connell JE, Kearns GJ. Submental intubation: a retrospective review of 45 cases. *Ir J Med Sci* 2013;182(03):309–313
- Hernández Altemir F. The submental route for endotracheal intubation. A new technique. *J Maxillofac Surg* 1986;14(01):64–65
- Kaiser A, Semanoff A, Christensen L, Sadoff R, DiGiacomo JC. Submental intubation: an underutilized technique for airway management in patients with panfacial trauma. *J Craniofac Surg* 2018;29(05):1349–1351
- Kita R, Kikuta T, Takahashi M, et al. Efficacy and complications of submental tracheal intubation compared with tracheostomy in maxillofacial trauma patients. *J Oral Sci* 2016;58(01):23–28
- Rodrigues WC, de Melo WM, de Almeida RS, Pardo-Kaba SC, Sonoda CK, Shinohara EH. Submental intubation in cases of panfacial fractures: a retrospective study. *Anesth Prog* 2017;64(03):153–161
- Nahum AM. The biomechanics of maxillofacial trauma. *Clin Plast Surg* 1975;2(01):59–64
- Follmar KE, Debruijn M, Baccarani A, et al. Concomitant injuries in patients with panfacial fractures. *J Trauma* 2007;63(04):831–835

- 20 Mulligan RP, Mahabir RC. The prevalence of cervical spine injury, head injury, or both with isolated and multiple craniomaxillofacial fractures. *Plast Reconstr Surg* 2010;126(05):1647–1651
- 21 Alvi A, Doherty T, Lewen G. Facial fractures and concomitant injuries in trauma patients. *Laryngoscope* 2003;113(01):102–106
- 22 Lee TS, Ducic Y, Gordin E, Stroman D. Management of carotid artery trauma. *Craniomaxillofac Trauma Reconstr* 2014;7(03):175–189
- 23 Jose A, Nagori SA, Agarwal B, Bhutia O, Roychoudhury A. Management of maxillofacial trauma in emergency: an update of challenges and controversies. *J Emerg Trauma Shock* 2016;9(02):73–80
- 24 Curtis W, Horswell BB. Panfacial fractures: an approach to management. *Oral Maxillofac Surg Clin North Am* 2013;25(04):649–660
- 25 Degala S, Sundar SS, Mamata KS. A comparative prospective study of two different treatment sequences i.e. bottom up-inside out and topdown-outside in, in the treatment of panfacial fractures. *J Maxillofac Oral Surg* 2015;14(04):986–994
- 26 Borad V, Lacey MS, Hamlar DD, Dresner HS, Yadava GK, Schubert W. Intraoperative imaging changes management in orbital fracture repair. *J Oral Maxillofac Surg* 2017;75(09):1932–1940
- 27 Cuddy K, Khatib B, Bell RB, et al. Use of intraoperative computed tomography in craniomaxillofacial trauma surgery. *J Oral Maxillofac Surg* 2018;76(05):1016–1025
- 28 Munding GS, Borsuk DE, Okhah Z, et al. Antibiotics and facial fractures: evidence-based recommendations compared with experience-based practice. *Craniomaxillofac Trauma Reconstr* 2015;8(01):64–78
- 29 He D, Zhang Y, Ellis E III. Panfacial fractures: analysis of 33 cases treated late. *J Oral Maxillofac Surg* 2007;65(12):2459–2465
- 30 Kupfer P, Cheng A, Patel A, Amundson M, Dierks EJ, Bell RB. Virtual surgical planning and intraoperative imaging in management of ballistic facial and mandibular condylar injuries. *Atlas Oral Maxillofac Surg Clin North Am* 2017;25(01):17–23
- 31 Khader R, Wallender A, Van Sickels JE, Cunningham LL. Secondary reconstruction of panfacial fractures. *Oral Maxillofac Surg* 2014;18(01):99–109
- 32 Thor A. Preoperative planning of virtual osteotomies followed by fabrication of patient specific reconstruction plate for secondary correction and fixation of displaced bilateral mandibular body fracture. *Craniomaxillofac Trauma Reconstr* 2016;9(02):188–194
- 33 Herford AS, Miller M, Lauritano F, Cervino G, Signorino F, Maiorana C. The use of virtual surgical planning and navigation in the treatment of orbital trauma. *Chin J Traumatol* 2017;20(01):9–13
- 34 Kärkkäinen M, Wilkman T, Mesimäki K, Snäll J. Primary reconstruction of orbital fractures using patient-specific titanium milled implants: the Helsinki protocol. *Br J Oral Maxillofac Surg* 2018;56(09):791–796