

HOSPITAL "MIGUEL SERVET" OF ZARAGOZA

DEPARTMENT OF ORAL AND MAXILLOFACIAL SURGERY

HEAD OF THE DEPARTMENT

FRANCISCO HERNANDEZ ALTEMIR, M.D.

"RETRONASAL INTUBATION" A NEW TECHNIQUE "INTUBACION RETRONASAL" UNA NUEVA TECNICA

FRANCISCO HERNANDEZ ALTEMIR, M.D.

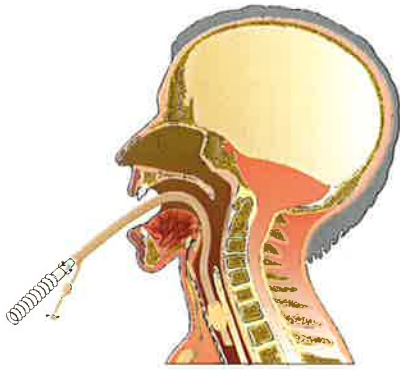


Fig. 1 : The retronasal intubation begins with a conventional orotracheal intubation.

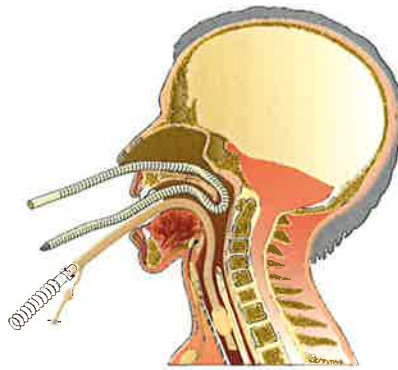


Fig. 2 : A cava catheter or a ringed Rusch catheter is passed through the chosen naris towards the cavum and oropharynx to come out through the mouth.

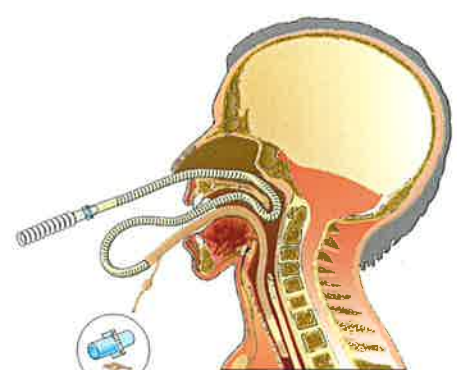


Fig. 3 : The cuff (balloon) stopper is released; the cava catheter, now with the ventilator connexion, is attached to the orotracheal tube.

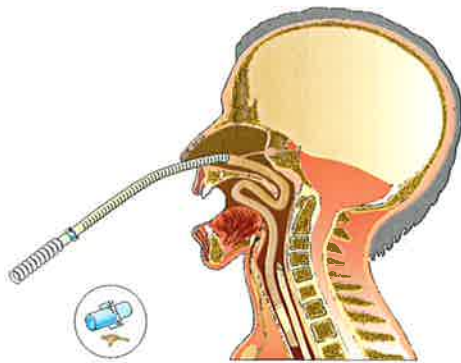


Fig. 4 : Pulling the cava catheter, the orotracheal tube is manually guided towards rinopharynx and coana, to be placed in the corresponding nasal fossa together with the deflated cuff-the cuff stopper is previously cut to the tube pass-

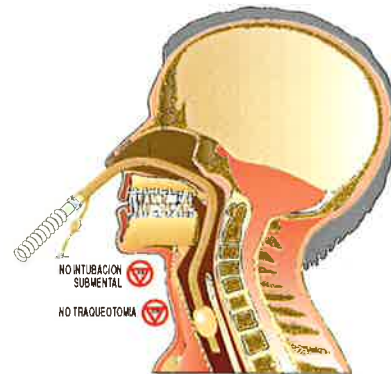


Fig. 5 : The orotracheal tube is now nasotracheal. The cuff can be inflated and occluded with the cut stopper.

RETRONASAL INTUBATION

The patient is orally intubated with a ringed tube of the size we would use for a nasal intubation. Whenever needed along the surgical procedure, we introduce through the chosen naris a ringed Rusch catheter (rather than a cava catheter) of a diameter one unit below that of the orotracheal tube in the patient, pushing it to the oropharyngeal cavity. Then, either manually or by some kind of clamp (a Magill clamp, of the kind used in anaesthesiology, for instance), it is pulled out through the oral cavity. Immediately, the orotracheal tube is detached from the ventilator and attached to the distal end of the Rusch catheter, in such a way that both tubes are tightly joined to stand the progressive traction and slight turns that are necessary to pull them out through rinopharynx, choana nasal fossa and naris, just like if it were a nasal intubation. All these handlings must take place with the cuff deflated, which must go through the same spaces as the nasotracheal tube, of which it is a part. This way it is possible to change an oral intubation into nasal intubation without removing the tracheal tube from its conventional place in the trachea. This manoeuvre enables us to work without the annoyance that would cause the tube if it were placed in the nasal region since the first moment. Besides, placing it in the nasal region from the mouth allows to perform intermaxillary blockades and as many intra or extraoral manoeuvres as we consider adequate.

ACKNOWLEDGEMENTS: TO THE DEPARTMENTS OF ANAESTHESIOLOGY AND REANIMATION AND INTENSIVE CARE OF THE HOSPITAL "MIGUEL SERVET" OF ZARAGOZA.

FIRST COMMUNICATION AT: SYMPOSIUM DISMANTLING AND REASSEMBLY OF THE FACIAL SKELETON-STATE OF THE ART-CASTELLANZA (VA)-NOVEMBER 26, 1994.

Under the patronage of the EUROPEAN ASSOCIATION FOR CRANIOMAXILLOFACIAL SURGERY, EUROPEAN SKULL BASE AND ITALIAN SOCIETY FOR MAXILLOFACIAL SURGERY.

XIII CONGRESO NACIONAL DE LA SOCIEDAD ESPAÑOLA DE CIRUGIA ORAL Y MAXILOFACIAL
PAMPLONA-IRUÑA 29-30-31 MAYO - DONOSTIA-SAN SEBASTIAN 31 MAYO - 1-2-3 JUNIO