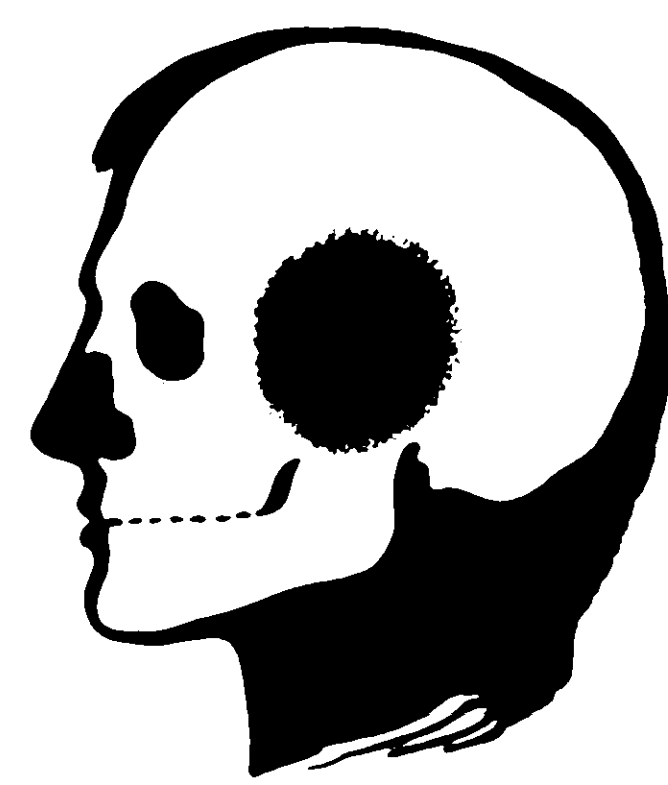


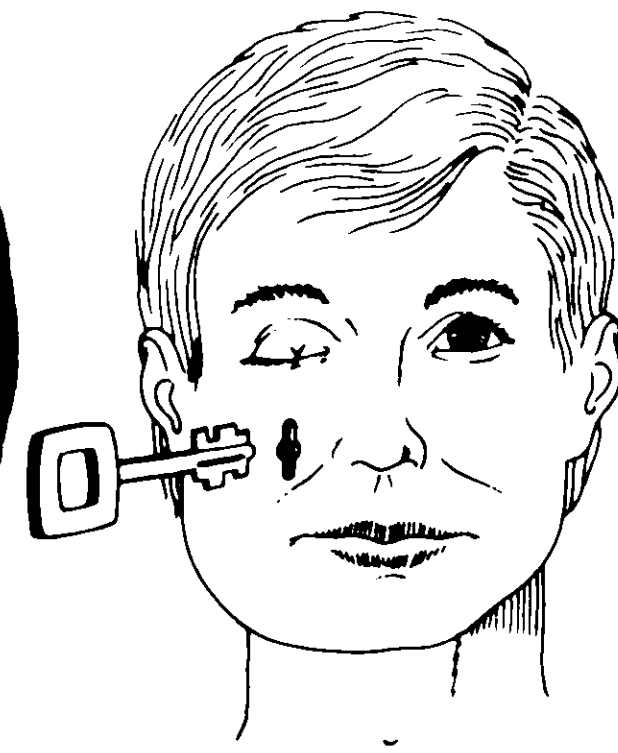
Department of Oral and Maxillofacial Surgery «Miguel Servet Hospital», Zaragoza
TRANSFACIAL ACCES TO THE RETROMAXILLARY AREA AND SOME TECHNICAL MODIFICATIONS

By Dr. F. HERNANDEZ ALTEMIR
 DEPARTMENT HEAD

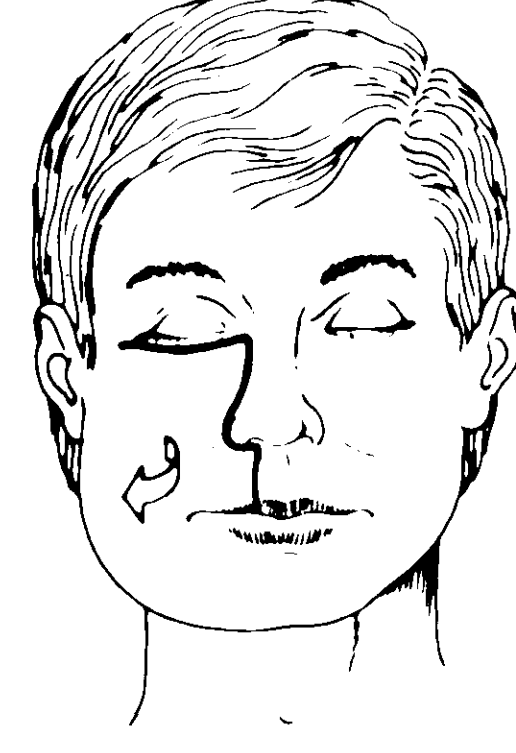
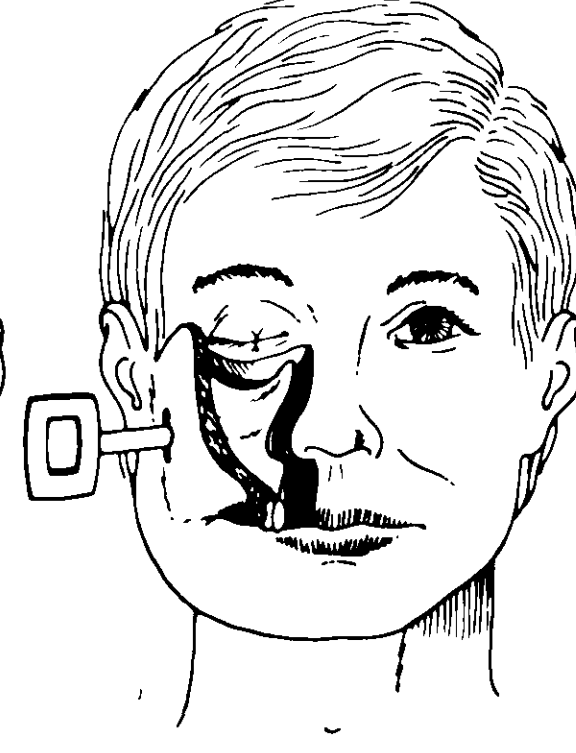
BASIC SERIES
 Greater Unilateral Technique
 Generalities:



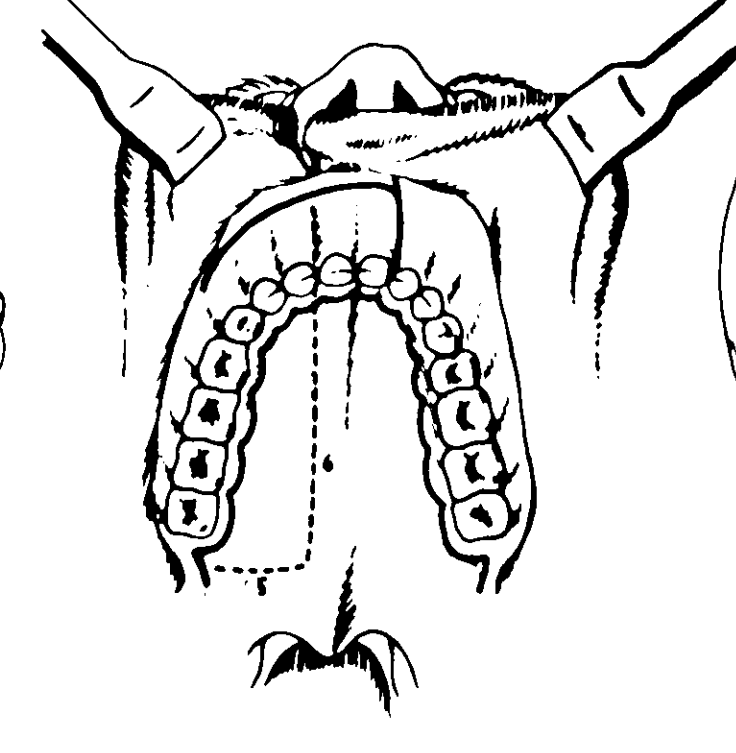
I
 How to reach the pterygomaxillary region.



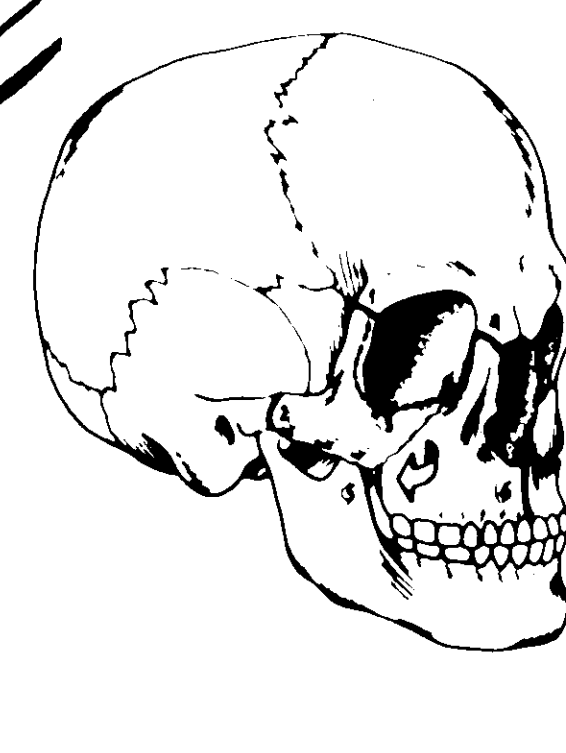
II and III
 Entry by opening the upper maxilla.
 Description of the greater unilateral technique.



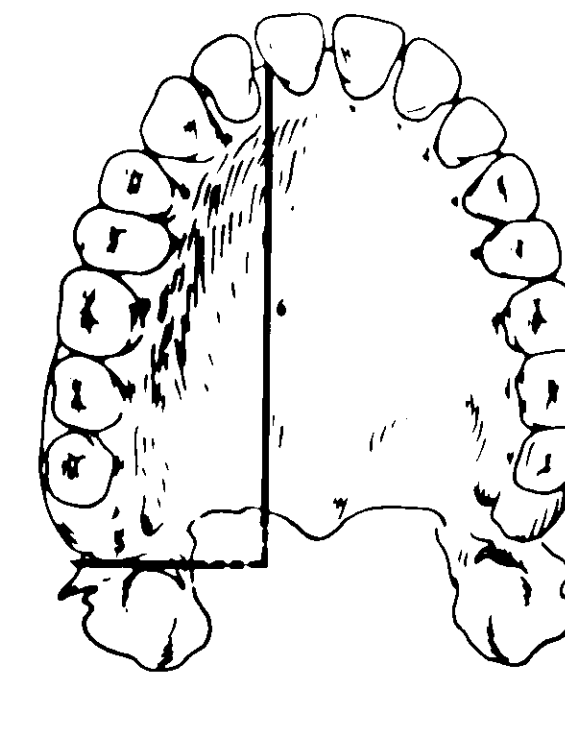
IV
 Cutaneous incision.



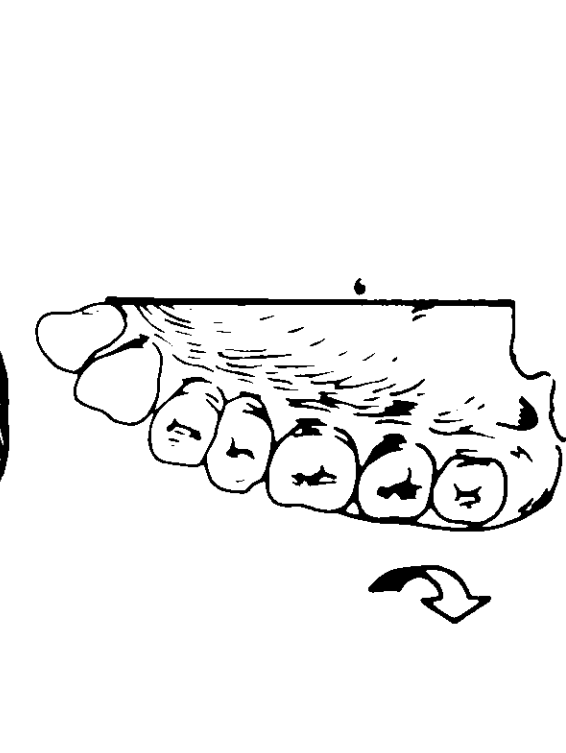
V
 Incisions in the vestibular and palatine mucosa, at points, detail of the osteotomy line.



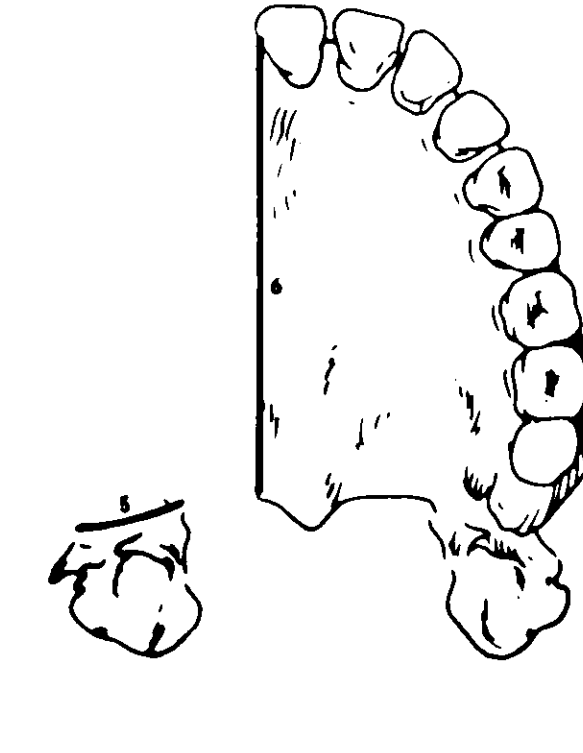
VI
 Most common course and order of the osteotomies 1, 2, 3, 4, 5 and 6.



VII
 Pterygopalatine osteotomies 5 and 6.




VIII
 Luxated maxilla.

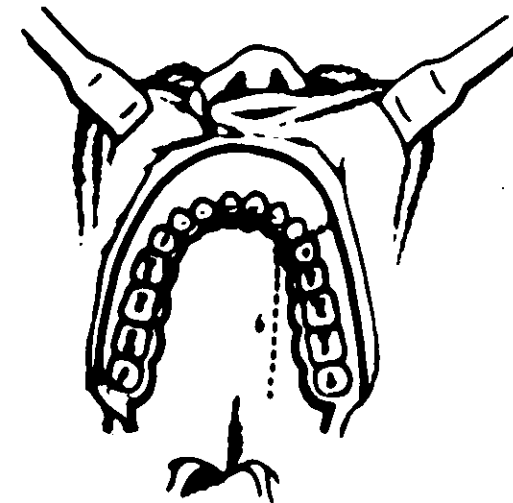


IX
 Final aspect after completing the osteotomies and with maxilla mobilized.

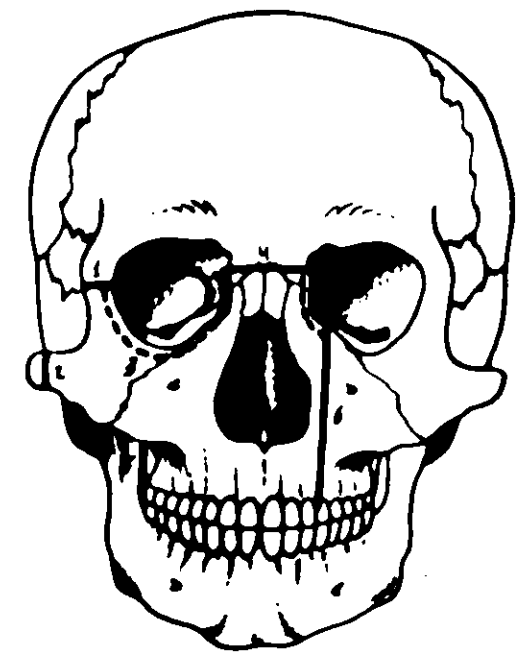
Greater unilateral technique including internal and external structures



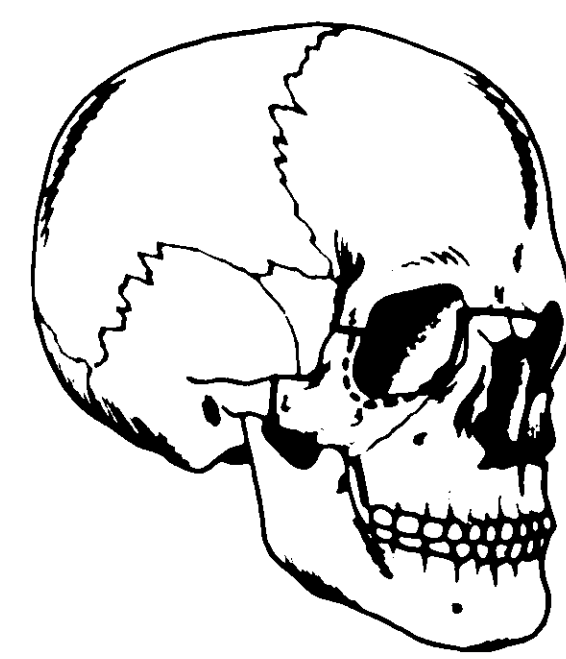
X
 Cutaneous incisions, the left subpalpebral can be extended along the whole line of dots.



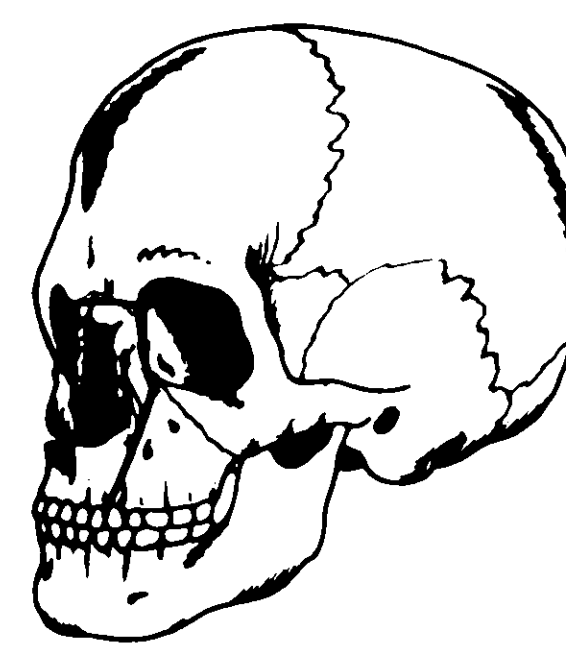
XI
 Incisions in the vestibular and palatine mucosa in thick line on dots line osteotomies.



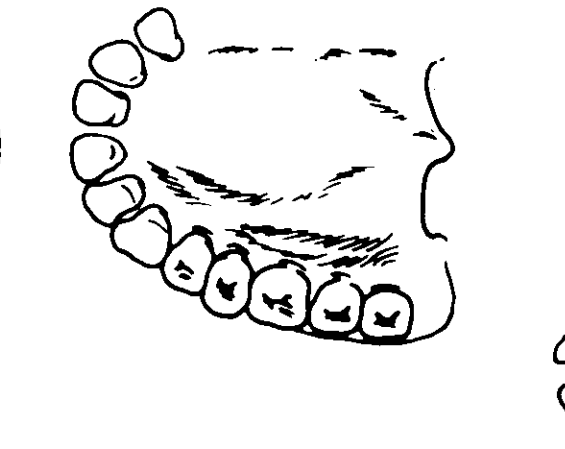
XII
 Osteotomies 1, 2, 3, 4, 5 and 6.



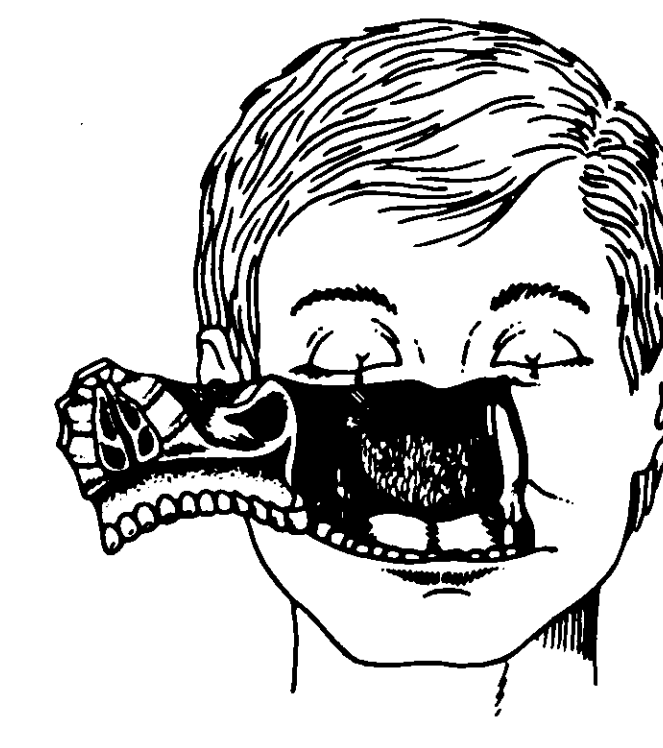
XIII
 Right-hand side view of the osteotomies 1, 2, 3, 4, 5.



XIV
 Left-hand side view of the osteotomies 4, 3, 6.



XV
 The whole of the upper left maxilla has been mobilized and part of the right-hand one.



XVI
 Aspect of the operative field after performing the mobilization of the maxilla and the nasal structures.

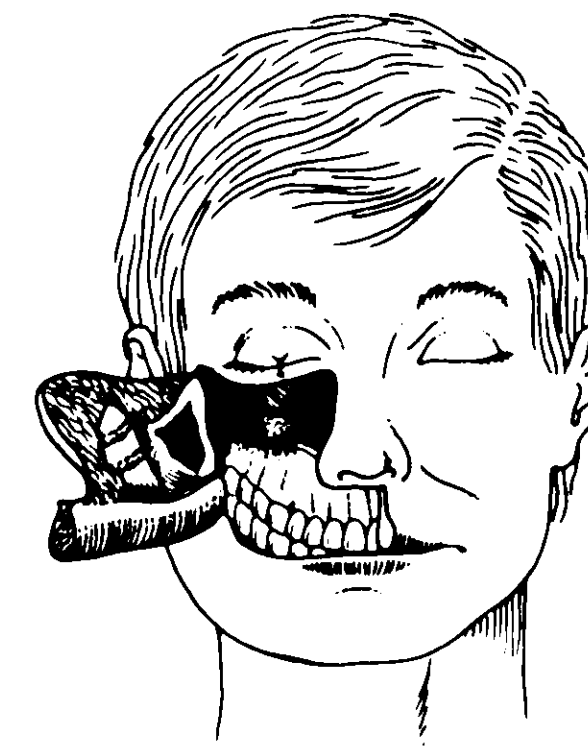


XVII
 The same aspect of Fig. 16, only greater decollement of the soft parts of the left side and of the upper left vestibular mucosa in the vestibular base.

OTHER POSSIBILITIES

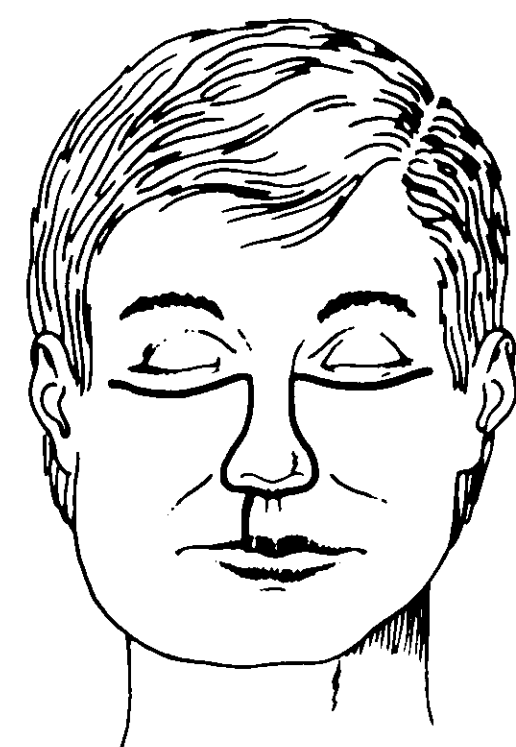
Minor unilateral technique

(It does not include the infrastructure of the hemimaxilla which is pedicled or mobilized).

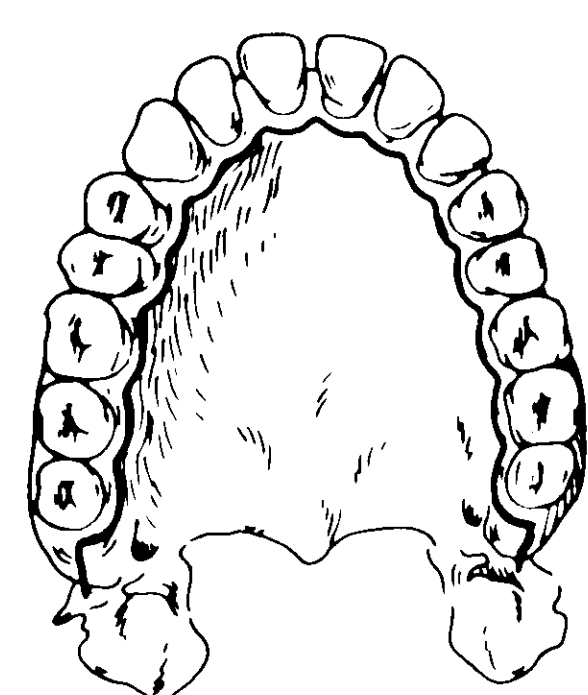


XVIII
 The intermaxilla relation is kept whole!

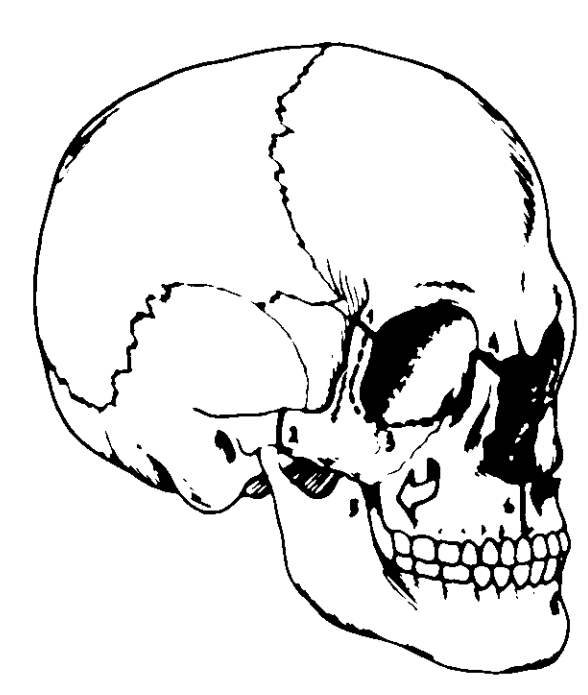
Greater bilateral technique



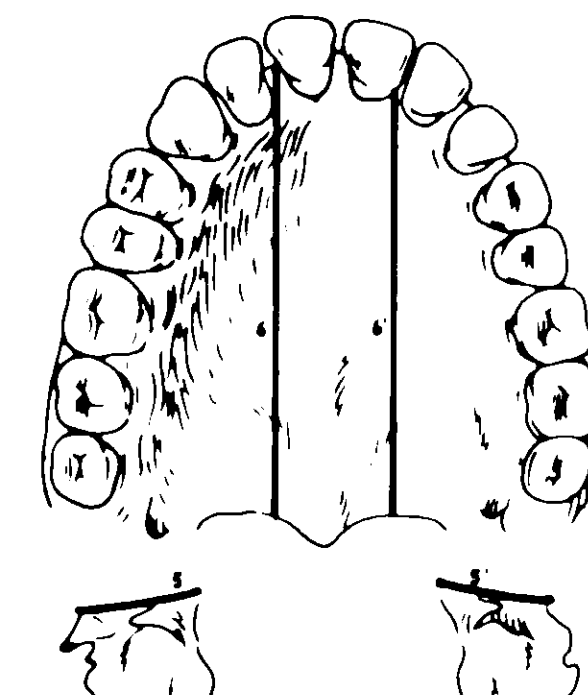
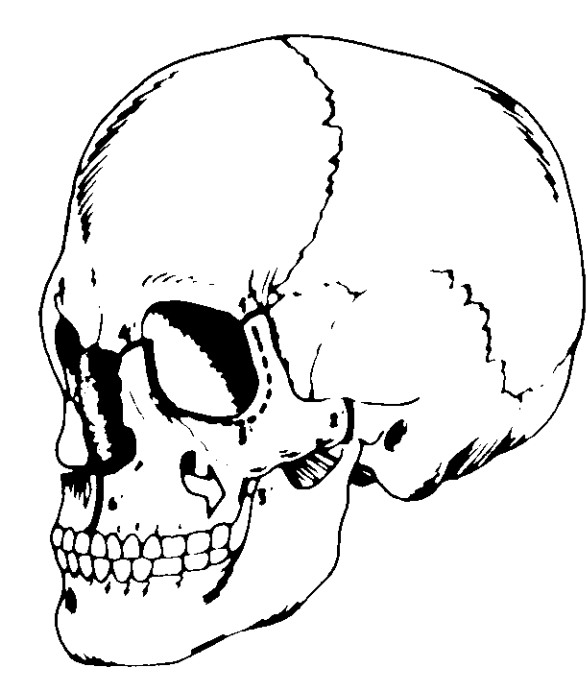
XIX
 Cutaneous incisions.



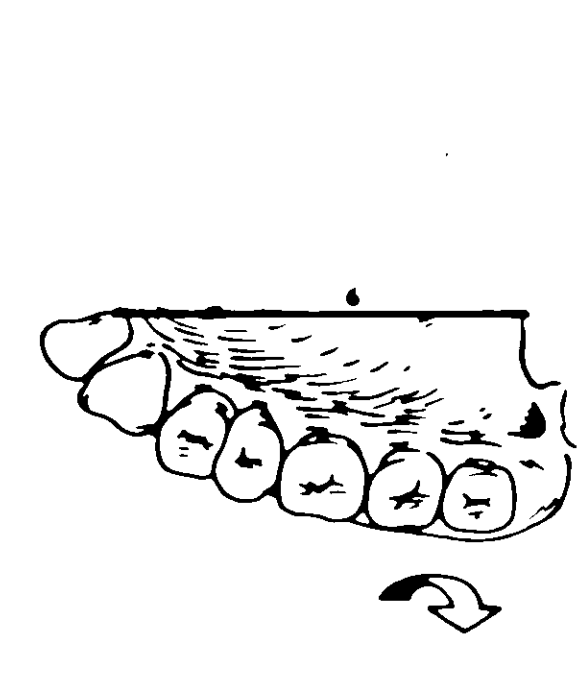
XX
 Incision in the palatine fibromucosa, which will unstuck.



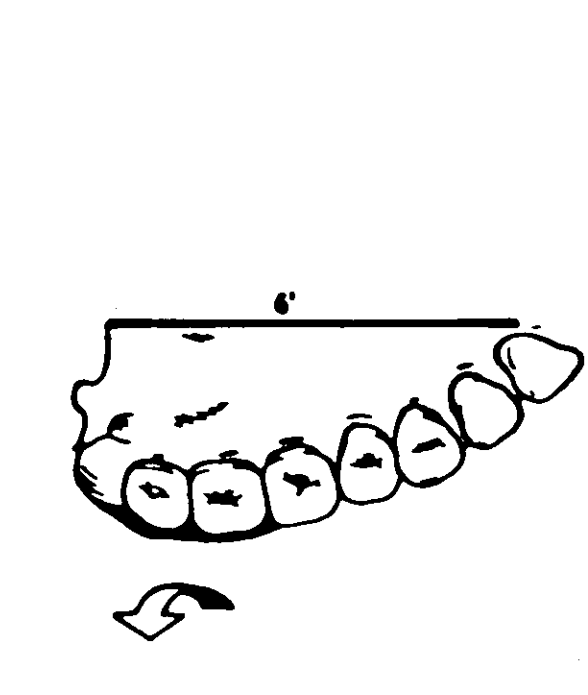
XXI and XXII
 Osteotomies 1, 2, 3, 4, 5, 6 and 1', 2', 3', 4', 5', 6' corresponding to the right and left sides respectively.



XXIII
 Pterygomaxillary and palatine osteotomies 5, 6 and 5', 6'.



XXIV
 The maxillas separated from the pterygoid and paraseptal regions.



XXV
 Final aspect, the face is open like a book!