

TRANSFACIAL ACCESS TO THE RETROMAXILLARY AREA

Dr. F. Hernández Altemir.

DEPARTMENT OF ORAL AND MAXILLOFACIAL SURGERY,
(HEAD: F. HERNANDEZ ALTEMIR, M.D., D.M.D),
HOSPITAL "MIGUEL SERVET", ZARAGOZA, SPAIN.

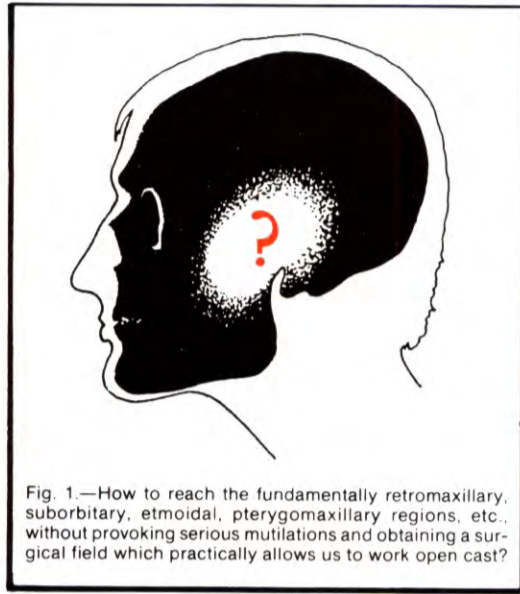


Fig. 1.—How to reach the fundamentally retromaxillary, suborbital, etmoidal, pterygomaxillary regions, etc., without provoking serious mutilations and obtaining a surgical field which practically allows us to work open cast?

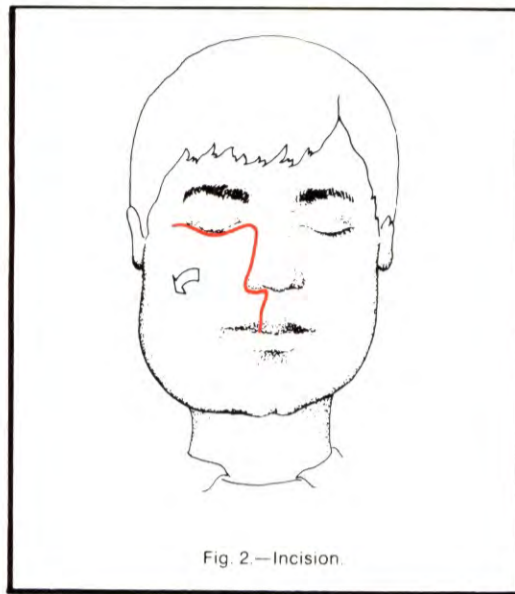


Fig. 2.—Incision.

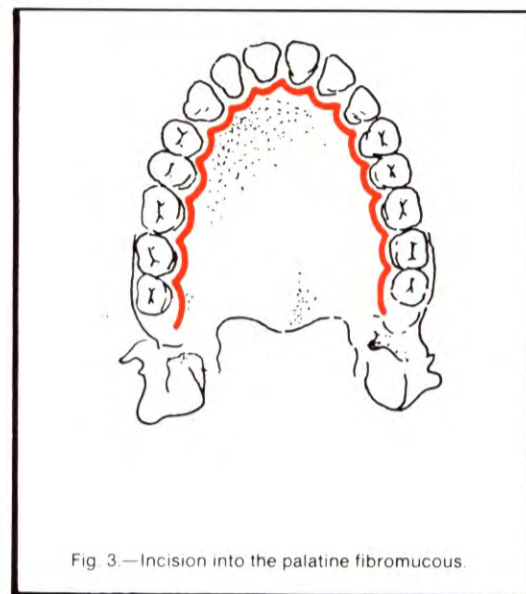


Fig. 3.—Incision into the palatine fibromucous.

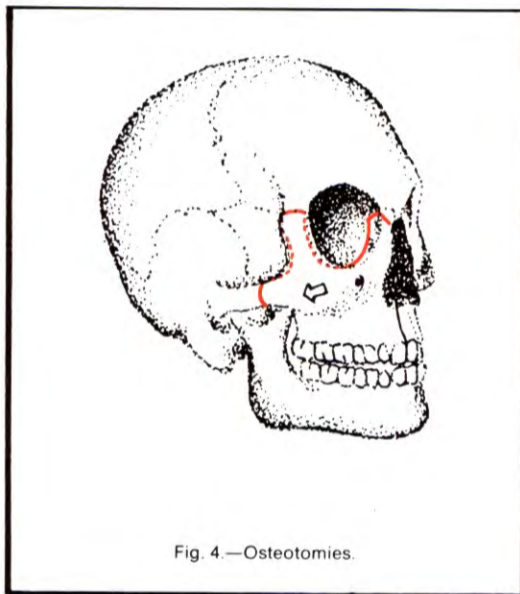


Fig. 4.—Osteotomies.

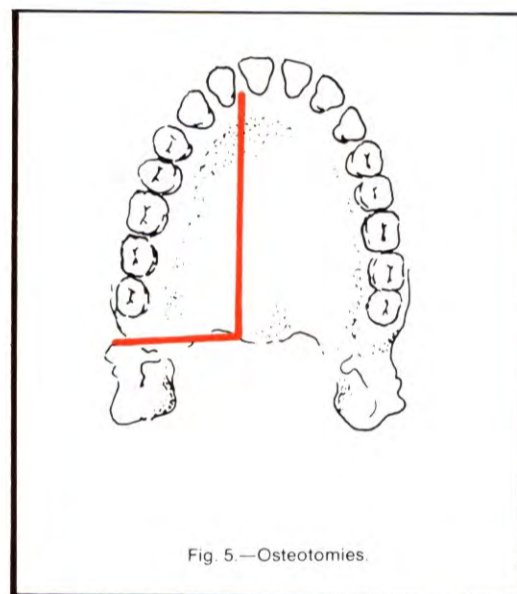


Fig. 5.—Osteotomies.

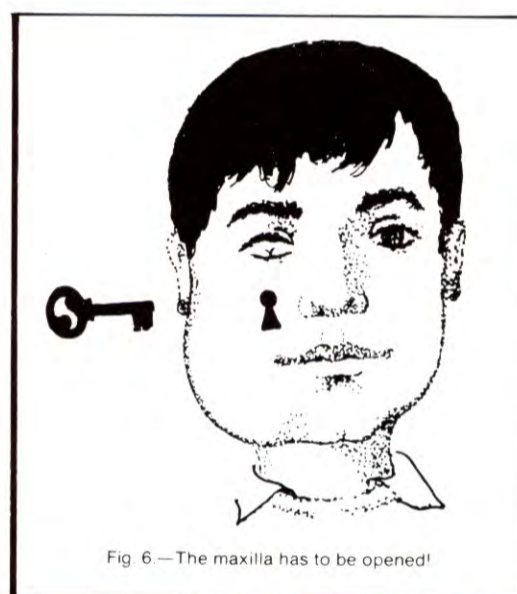


Fig. 6.—The maxilla has to be opened!

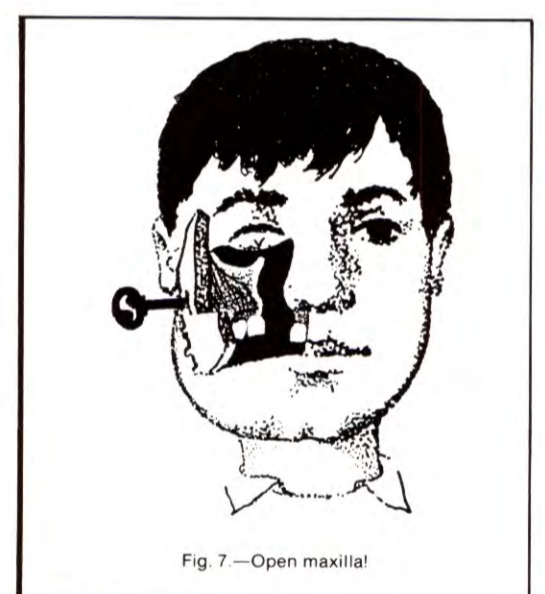


Fig. 7.—Open maxilla!

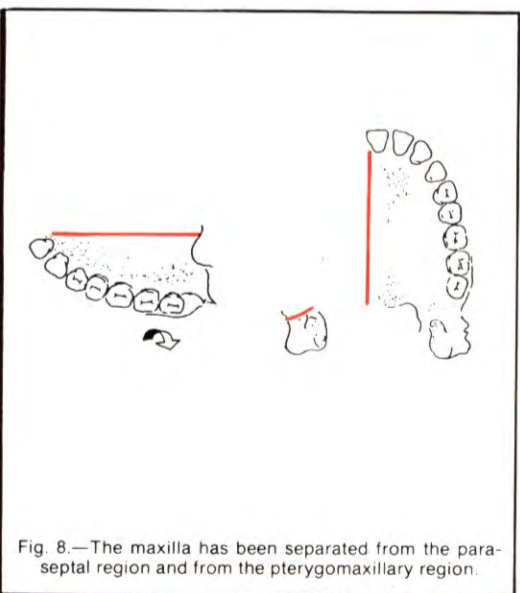


Fig. 8.—The maxilla has been separated from the parasseptal region and from the pterygomaxillary region.

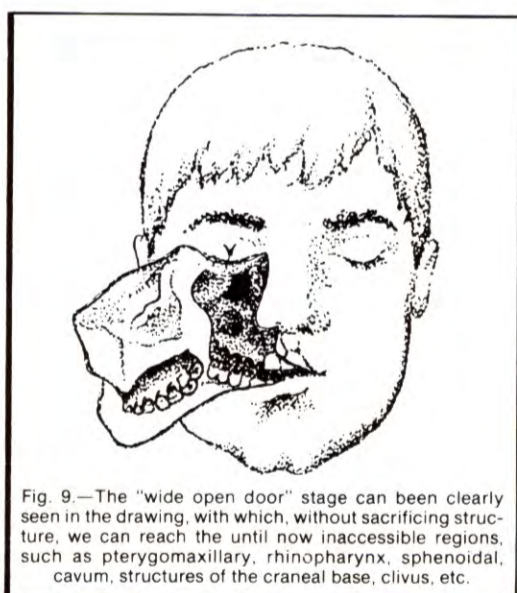


Fig. 9.—The "wide open door" stage can be clearly seen in the drawing, with which, without sacrificing structure, we can reach the until now inaccessible regions, such as pterygomaxillary, rhinopharynx, sphenoidal, cavum, structures of the cranial base, clivus, etc.

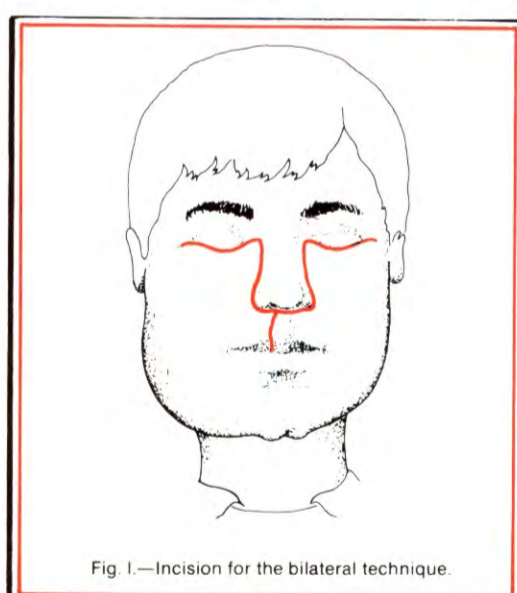


Fig. 10.—Incision for the bilateral technique.

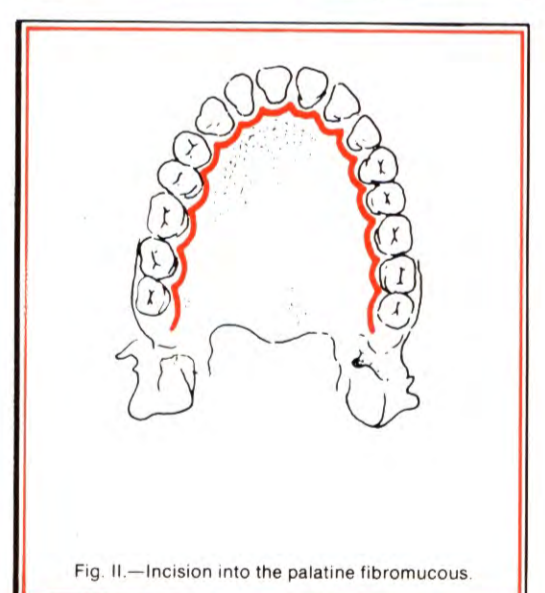


Fig. 11.—Incision into the palatine fibromucous.

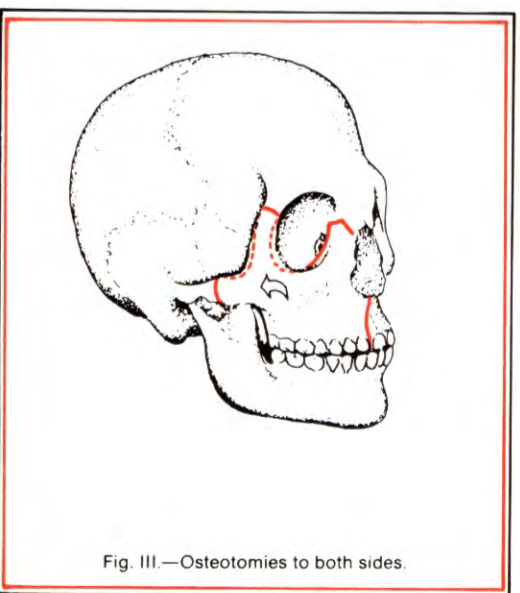


Fig. 12.—Osteotomies to both sides.

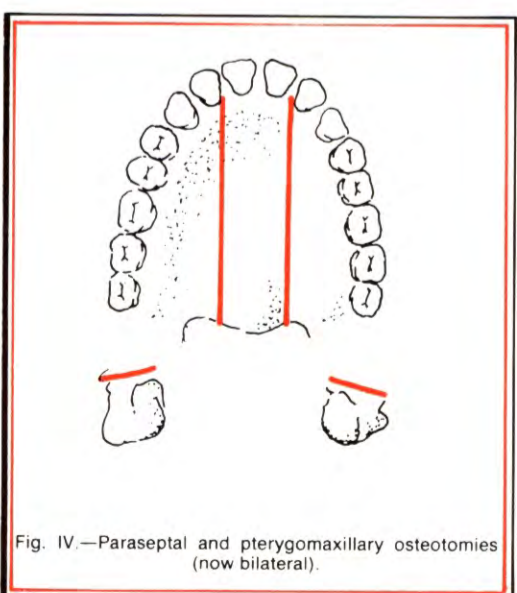


Fig. 13.—Parasseptal and pterygomaxillary osteotomies (now bilateral).

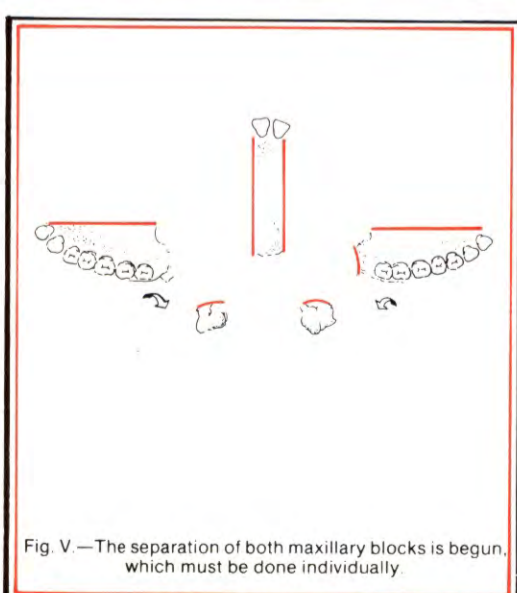


Fig. 14.—The separation of both maxillary blocks is begun, which must be done individually.

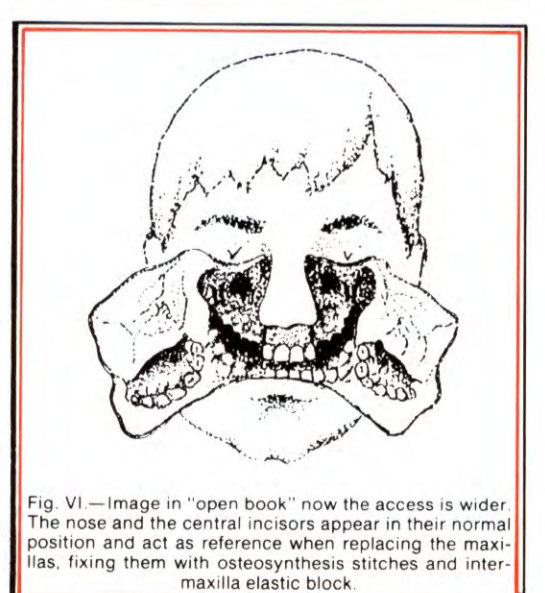


Fig. 15.—Image in "open book" now the access is wider. The nose and the central incisors appear in their normal position and act as reference when replacing the maxillas, fixing them with osteosynthesis stitches and intermaxilla elastic block.